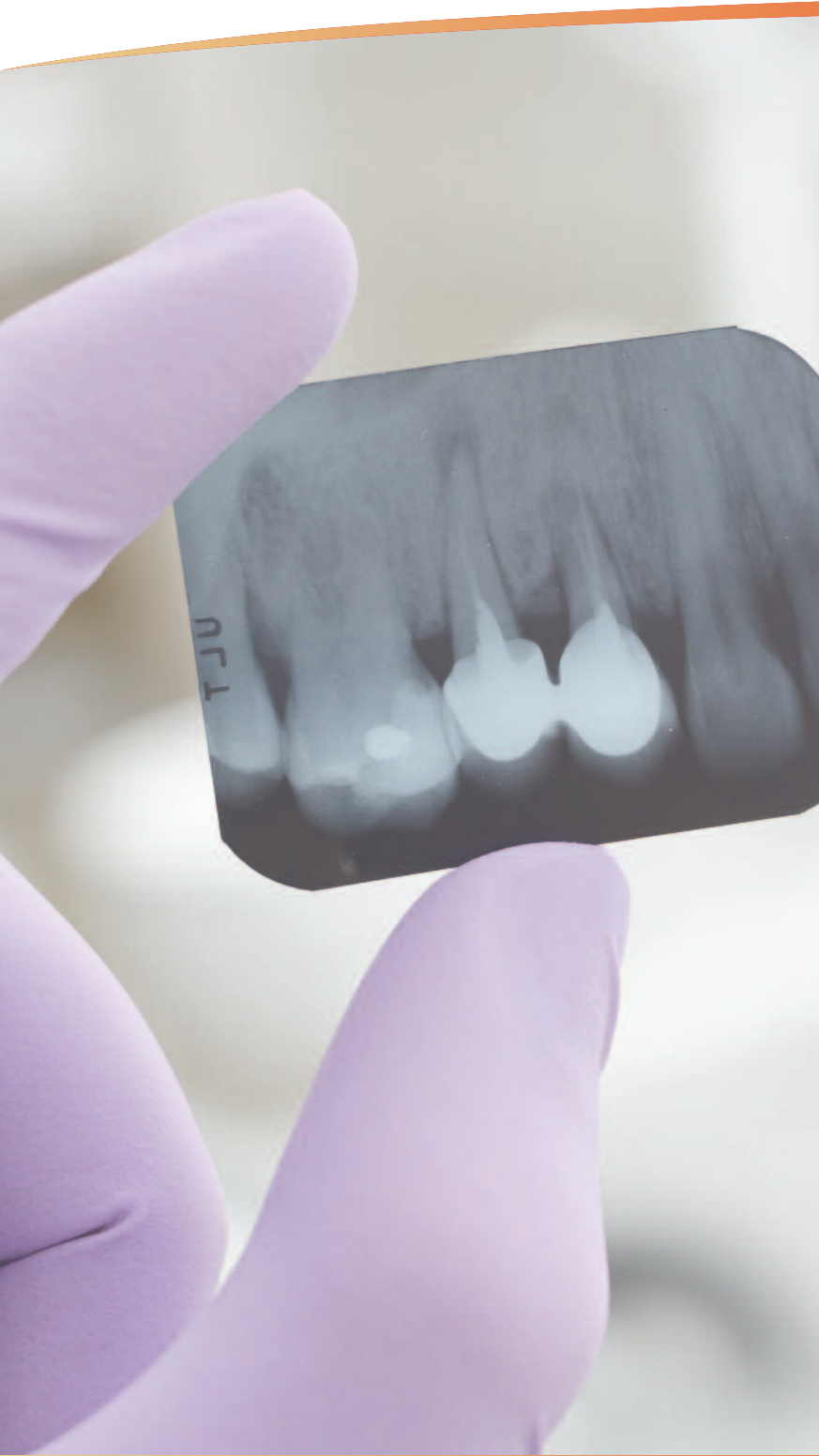


Septodont Case Studies Collection

No. 08 - June 2014

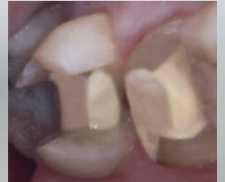

Focus on:

BIODENTINE™

PULP PRESERVATION IN
PROSTHETIC ABUTMENTS

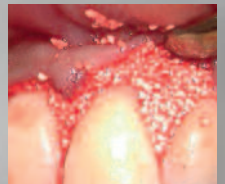ATHINA BAKOPOULOU
AND IMAD ABOUT



R.T.R.

AND AGGRESSIVE
PERIODONTITIS

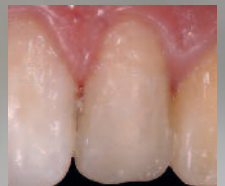DJAMILA BOUZIANE,
KHADIDJA L. MAKRELOUF
AND MOHAMED BOUZIANE



N'DURANCE®

POST-ORTHODONTIC
MODIFICATION OF
AESTHETICS

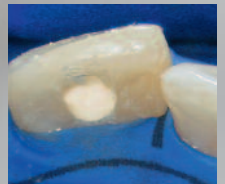CHRISTINA BOUTSIOUKI
AND PARIS GERASIMOU



BIODENTINE™

VITAL PULP THERAPY
IN TRAUMATIZED TEETH

MARGA REE



Editorial

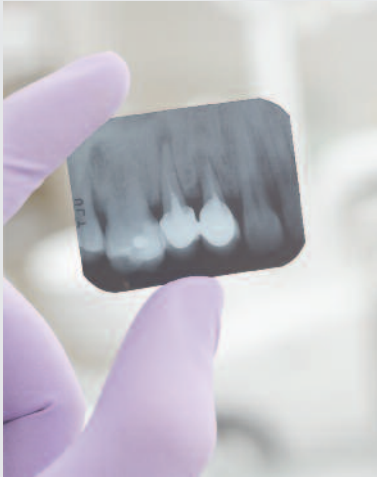

Photo © Miroslubac / Dreamstime

Since its foundation Septodont has developed, manufactured and distributed a wide range of high quality products for dental professionals.

Septodont recently innovated in the field of gingival preparation, composites and dentine care with the introduction of Racegel, the N'Durance® line and Biodentine™, which are appreciated by clinicians around the globe.


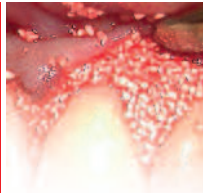

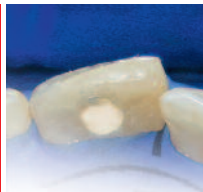
Septodont created the “Septodont Case Studies Collection” to share their experience and the benefits of using these innovations in your daily practice.

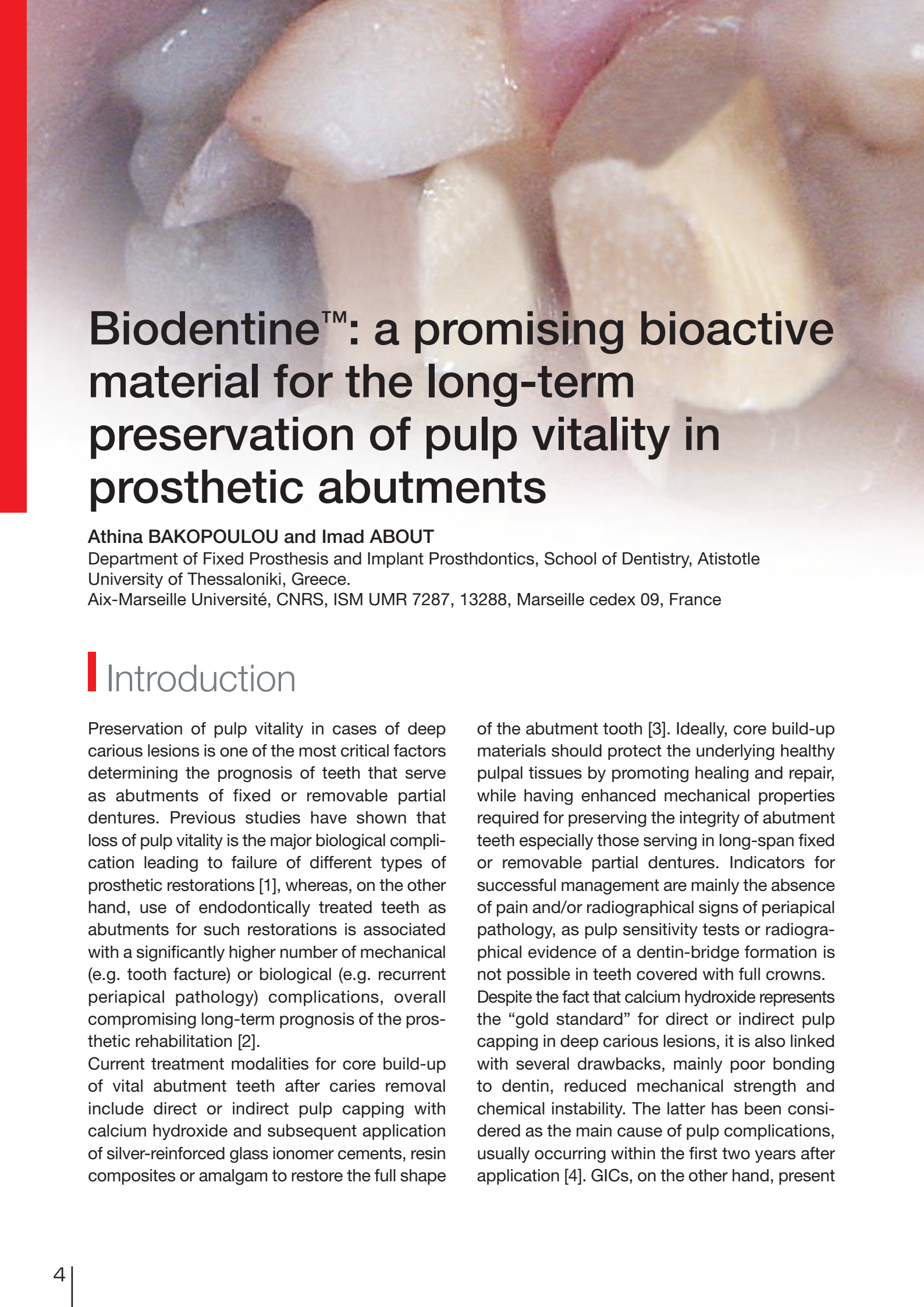
This Collection consists in a series of case reports and is published on a regular basis.

This 8th issue is dedicated to three of Septodont's innovative products:

- Biodentine™, the first biocompatible and bioactive dentin replacement material. Biodentine™ uniqueness not only lies in its innovative bioactive and “pulp-protective” chemistry, but also in its universal application, both in the crown and in the root.
- R.T.R., an easy-to-use synthetic bone grafting material. In addition to its ability to provide an optimal osteoconductive environment to promote the growth of new dense bone, R.T.R. comes in 3 different presentations to suit all the clinical situations.
- N'Durance®, the first universal composite based on our exclusive Nano-Dimer Technology. N'Durance® unique combination of low shrinkage and high conversion offers extra biocompatibility and durability to your restorations.

Content

	Biodentine™: pulp preservation in prosthetic abutments Athina BAKOPOULOU and Imad ABOUT	07
	R.T.R. and aggressive periodontitis D. BOUZIANE / K. L. MAKRELOUF / M. BOUZIANE	14
	N'Durance®: Post-Orthodontic modification of aesthetics Christina BOUTSIOUKI and Paris GERASIMOU	22
	Biodentine™: Vital pulp therapy in traumatized teeth Marga REE	28

A close-up photograph of a tooth with a crown and a core build-up material. The crown is white and has a natural-looking appearance. The core build-up material is a light yellowish-brown color and is visible at the base of the crown. The background is a soft, out-of-focus pinkish-red color, likely representing the gum tissue.

Biodentine™: a promising bioactive material for the long-term preservation of pulp vitality in prosthetic abutments

Athina BAKOPOULOU and Imad ABOUT

Department of Fixed Prosthesis and Implant Prosthodontics, School of Dentistry, Atistotle University of Thessaloniki, Greece.

Aix-Marseille Université, CNRS, ISM UMR 7287, 13288, Marseille cedex 09, France

Introduction

Preservation of pulp vitality in cases of deep carious lesions is one of the most critical factors determining the prognosis of teeth that serve as abutments of fixed or removable partial dentures. Previous studies have shown that loss of pulp vitality is the major biological complication leading to failure of different types of prosthetic restorations [1], whereas, on the other hand, use of endodontically treated teeth as abutments for such restorations is associated with a significantly higher number of mechanical (e.g. tooth fracture) or biological (e.g. recurrent periapical pathology) complications, overall compromising long-term prognosis of the prosthetic rehabilitation [2].

Current treatment modalities for core build-up of vital abutment teeth after caries removal include direct or indirect pulp capping with calcium hydroxide and subsequent application of silver-reinforced glass ionomer cements, resin composites or amalgam to restore the full shape

of the abutment tooth [3]. Ideally, core build-up materials should protect the underlying healthy pulpal tissues by promoting healing and repair, while having enhanced mechanical properties required for preserving the integrity of abutment teeth especially those serving in long-span fixed or removable partial dentures. Indicators for successful management are mainly the absence of pain and/or radiographical signs of periapical pathology, as pulp sensitivity tests or radiographical evidence of a dentin-bridge formation is not possible in teeth covered with full crowns. Despite the fact that calcium hydroxide represents the “gold standard” for direct or indirect pulp capping in deep carious lesions, it is also linked with several drawbacks, mainly poor bonding to dentin, reduced mechanical strength and chemical instability. The latter has been considered as the main cause of pulp complications, usually occurring within the first two years after application [4]. GICs, on the other hand, present

chemical and mechanical stability, adhesive anchoring to the dentin and very acceptable biocompatibility, which are considered as significant advantages. However, they lack the required and particularly necessary dentin-forming effect that is to be expected [5]. Finally, composite resin materials have a questionable biological behavior, as several studies have shown that pulp inflammation leading to irreversible pulp damage may be developed when these materials are used for direct or indirect pulp capping, even in combination with calcium hydroxide [6, 7].

In 2010, a tricalcium-silicate based cement (Biodentine™, Septodont) became commercially available. Clinical and experimental results have already demonstrated a successful outcome with Biodentine™ when used for direct and indirect pulp capping procedures as well as in

endodontic applications. As main advantages of this material have been reported its ability to create a firm anchorage to dentin, its bioactivity leading to reparative dentin formation, its antibacterial effects and improved mechanical properties, which are similar to dentin [8-12]. However, data are completely lacking with respect to the potential application of this bioactive cement as a core-build up material underneath prosthetic restorations. Here we present two clinical cases of successful use of Biodentine™ in deep carious lesions in abutment teeth covered with full crowns. Collection of data concerning the clinical behavior of this material in such cases, will allow more extensive use under long-span fixed or removable partial dentures, establishing Biodentine™ as a bioactive core build-up material with a significant advantage in preserving pulp vitality of prosthetic abutments.

Clinical case 1

A 36 year-old female patient, with a medical history of systemic rheumatoid arthritis, came for her regular scheduled 6-month oral control. The patient had a history of frequent recurrent caries underneath existing restorations that remained symptom-free until the lesion reached the pulp cavity. Despite the fact that the patient was performing dental hygiene very thoroughly, radiographic examination revealed a secondary carious lesion at the distal margin of an existing crown in tooth # 16 (Fig. 1, 2). The patient was informed about the need of having the crown removed in order to treat caries and also for the potential that an endodontic treatment might be required before a new crown could be placed. After patient consent, local anesthesia was performed (Articaine HCL 4% and 1:200000 adrenaline, Ubistesin, 3M ESPE), the crown was removed and the carious dentin was completely excavated. At the distal area of the abutment tooth # 16 a very thin pulp facing layer of remaining dentin could be observed whereas a shallower cavity was observed at the proximal part of the abutment (Fig. 3, 4). Biodentine™ (Septodont) was

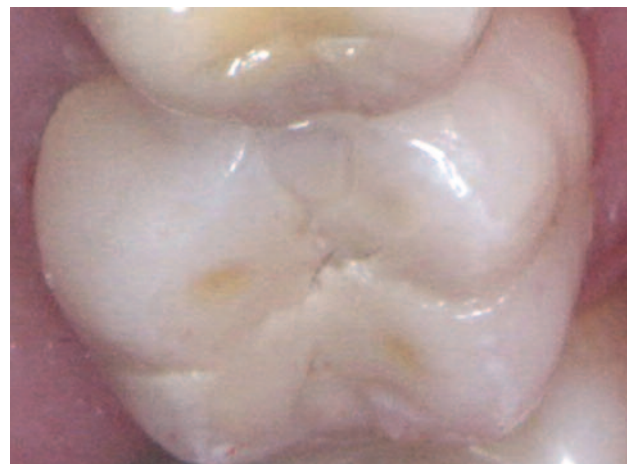

Fig. 1: Preoperative clinical photograph of existing crown on tooth # 16

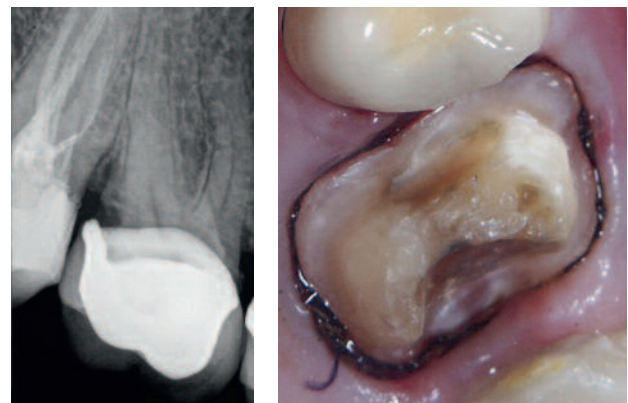


Fig. 2: Preoperative radiograph showing recurrent caries at the distal margin of existing crown on tooth # 16

Fig. 3: Clinical status after crown removal and caries excavation

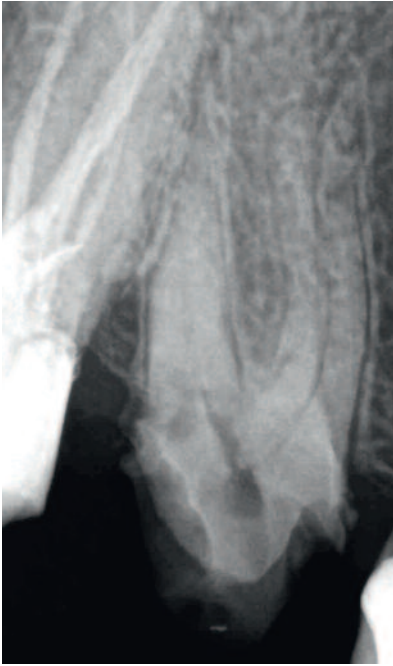

Fig. 4: Radiograph taken immediately after caries removal, showing close proximity of the cavity walls to the pulp, especially at the distal abutment wall

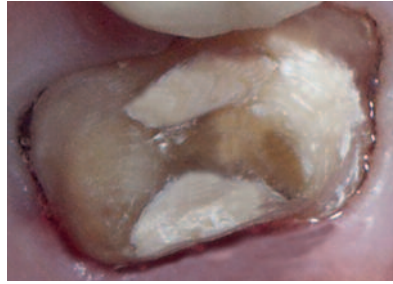


Fig. 5: Biodentine™ was used as a core build-up material

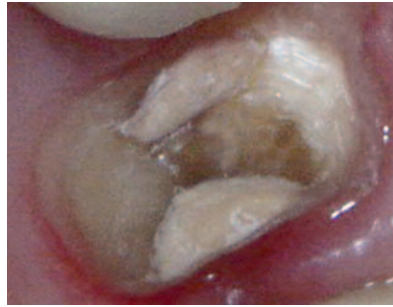

Fig. 6: Biodentine™ was left in place for 6 weeks. During this period the tooth remained symptom-free, whereas its integrity was maintained

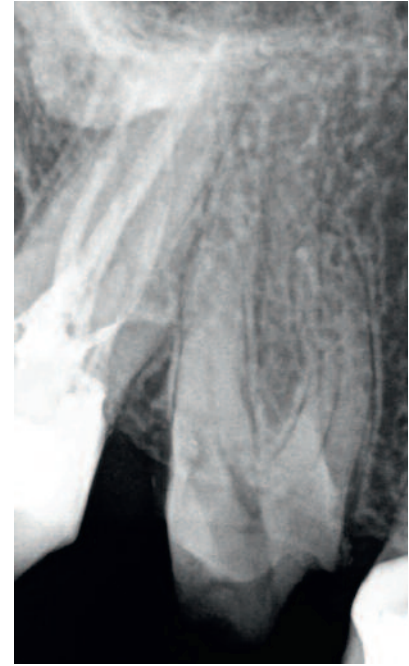

Fig. 7: Radiographic examination at 6 weeks revealed reparative dentin formation and lack of any periapical pathology

chosen as a core build-up material to fill both cavities (*Fig. 5*). The material was handled according to the manufacturer's instructions by mixing a single-unit powder part (tricalcium silicate-dicalcium silicate-zircon oxide) and 5 drops of a single unit liquid part (calcium chloride-distilled water) for 30 seconds in an automatic mixer. This decision to use Biodentine™ was based on a previous history of the patient of deep caries leading to pulp inflammation and or necrosis. Biodentine™ was left in place for 6 weeks in order to ensure preservation of pulp vitality (*Fig. 6, 7*). During this period the tooth was covered with a provisional crown (*Fig. 8*). After

the six week period, the patient reported that she remained symptom-free and the tooth was positive on CO₂ snow sensitivity and negative on percussion. Conventional restorative procedures were followed for the placement of a new metal ceramic crown (*Fig. 9*) with Biodentine™ remaining as a permanent core-build-up material. The crown was cemented with conventional glass-ionomer cement (Fuji I, GC). At the follow-up visit 6 months and 1 year after treatment the tooth remained free from any symptomatology. Radiographical examination showed no signs of periapical pathology or recurrent caries (*Fig. 10, 11*).

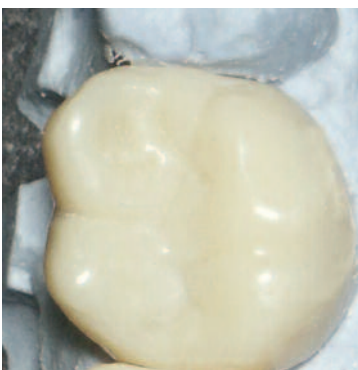

Fig. 8: A provisional restoration was used to cover the abutment tooth during the 6-week healing period

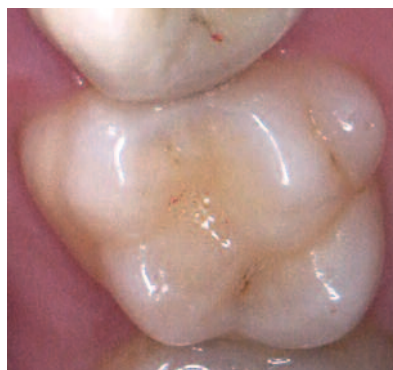

Fig. 9: Final metal ceramic crown placed after 8 weeks and cemented with conventional glass-ionomer cement (Fuji I, GC)

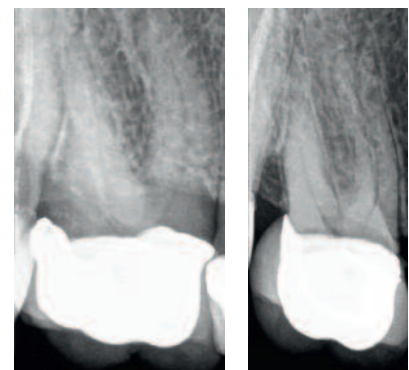


Fig. 10: Radiographic examination six months post-treatment. No signs of periapical pathology could be observed
Fig. 11: Radiographic examination 1 year post-treatment. The tooth remained free from any periapical pathology

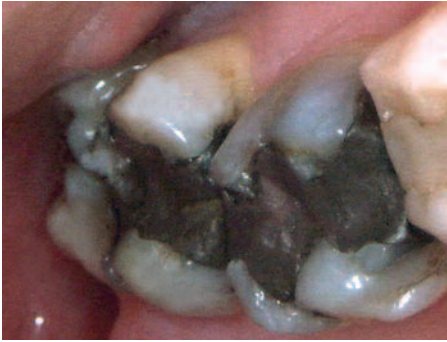

Fig. 12: Preoperative clinical picture showing existing amalgam restorations on teeth # 26 and # 27 accompanied with pulp symptomatology

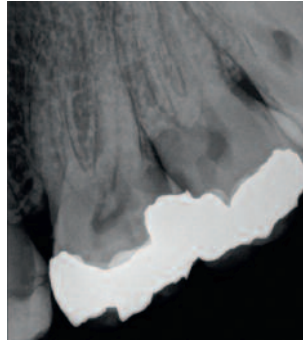


Fig. 13: Preoperative radiograph showing deep recurrent caries in teeth # 26 and 27 in close proximity to the pulp

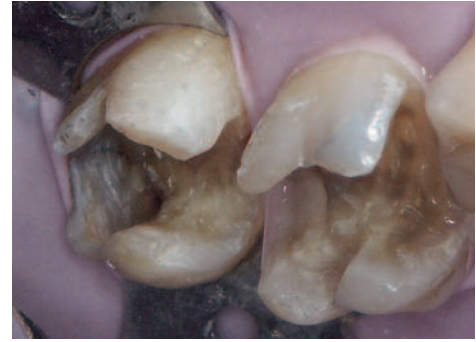


Fig. 14: After caries removal deep cavities in close proximity to the pulp were the case for both teeth

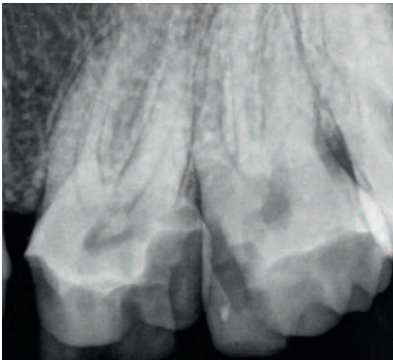


Fig. 15: Radiographic examination after caries removal confirming the close proximity of the cavity walls to the pulp chamber

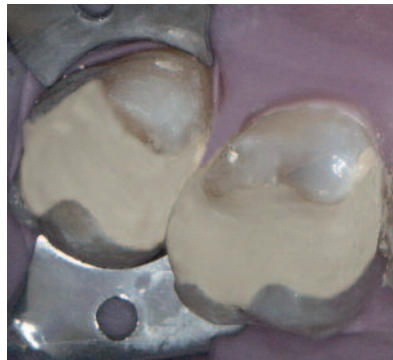


Fig. 16: Biodentine™ was placed as a bulk material to restore both cavities and left in place for 6 weeks. A rubber dam was used to avoid further bacterial contamination of the symptomatic pulps

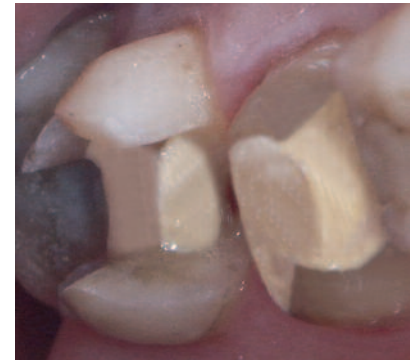

Fig. 17: Biodentine™ restorations 6 weeks after placement. Marginal integrity of both restorations was fully preserved and no fractures were observed. In tooth # 27 Biodentine™ was partially removed and kept as a base/dentin substitute for subsequent filling with a direct composite. Tooth # 26 was prepared for full coverage and Biodentine™ remained as an abutment build-up material

Clinical case 2

A 42 year-old female patient, with free medical history, came complaining for tooth pain at the upper left maxilla, both after consuming cold and hot beverages but also automatically. Diagnostic assessment and radiographic examination revealed recurrent carious lesions below existing amalgam restorations in teeth # 26 (distally) and # 27 (proximally) (*Fig. 12, 13*). Both teeth were positive on pulp sensitivity tests (CO₂ snow, hot gutta-percha and electrical stimulus sensitivity), although at a quite higher threshold compared to a normal pulp. Both teeth were also negative on percussion. The patient was informed about the need of having the carious lesions treated and the fillings repeated or in case of extensive caries replaced by full crowns. After patient consent, local anesthesia was performed (Articaine HCL 4% and 1:200000 adrenaline, Ubistesin, 3M ESPE), the amalgam

restorations were removed and the carious dentin was completely excavated leaving extensive deep cavities (*Fig. 14, 15*). Biodentine™ (Septodont) was chosen as a provisional filling material of the entire cavity of both teeth (*Fig. 16*). The material was handled according to the manufacturer's instructions. Biodentine™ was left in place for 6 weeks in order to ensure that pulp sensitivity would be eliminated while preserving pulp vitality. The patient remained symptom-free during the six week period, whereas both teeth were positive on pulp sensitivity tests and negative on percussion. Biodentine™ was then partially removed in tooth #27 to serve as a cavity liner, whereas tooth #26 was prepared to receive a full crown due to the significant loss of dental hard tissues after caries removal, with Biodentine serving as a dentin substitute for the abutment build-up (*Fig. 17*).

Following conventional restorative procedures (acid etching of the cavity with phosphoric acid and application of single step adhesive, Excite F, Ivoclar-Vivadent), tooth #27 was filled with a direct composite resin filling (Tetric EvoCeram Bulk Fill, Ivoclar-Vivadent) (Fig. 18) and tooth #26 was restored with a full crown after final impression with a polyvinylsiloxane impression material

(Affinis, Coltene-Whaledent) (Fig 19, 20). The crown was cemented with conventional glass-ionomer cement (Fuji I, GC). At the follow-up visit at 6 months and 1 year after treatment both teeth were free from any symptomatology. Radiographical examination showed no signs of periapical pathology (Fig. 21, 22).

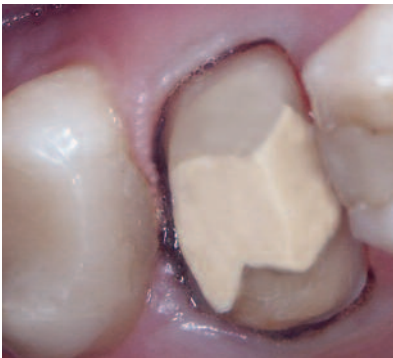

Fig. 18: Tooth # 27 was capped by a direct composite resin filling (Tetric EvoCeram Bulk Fill, Ivoclar-Vivadent) and tooth # 26 was prepared for a full crown

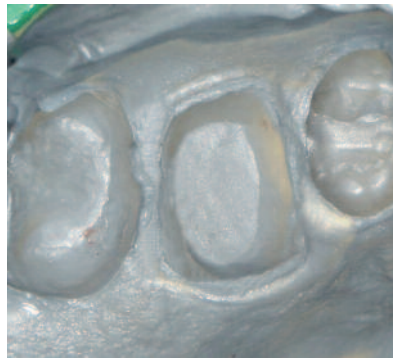

Fig. 19: Final impression was taken using a polyvinylsiloxane impression material (Affinis, Coltene-Whaledent)

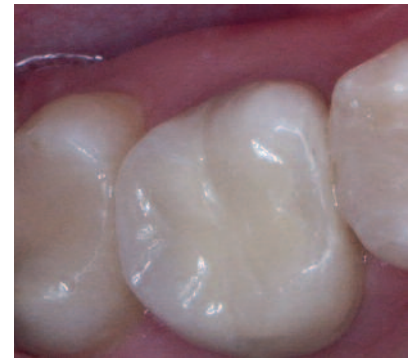

Fig. 20: Post-operative clinical picture with a direct resin composite filling in tooth # 27 and a metal ceramic crown in tooth # 26

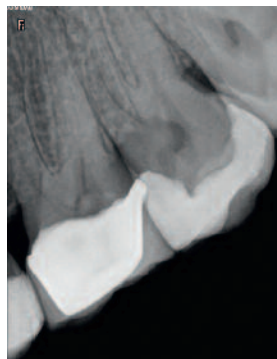
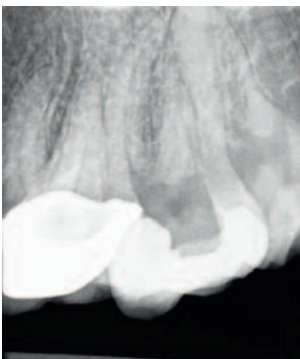

Fig. 21a & b: Radiographic examination six months post treatment. No signs of periapical pathology could be observed

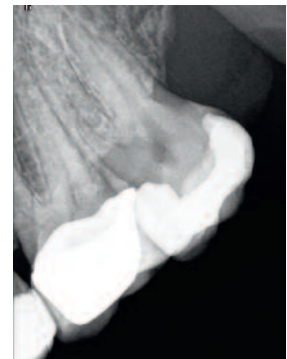
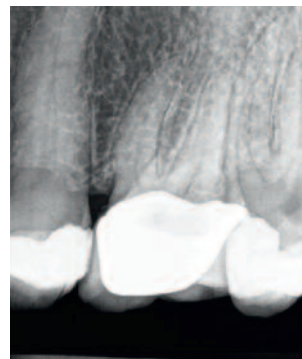


Fig. 22a & b: Radiographic examination 1 year post-treatment. The tooth remained free from any periapical pathology (the third molar # 28 was removed in the meantime due to recurrent caries)

Discussion

Studies have shown that metal-reinforced glass-ionomers and resin composites show acceptable clinical outcomes in prosthetic procedures requiring core-build up of abutment teeth (both vital and non-vital) [13, 14]. However, the main discriminating factors between materials used for core build-up of vital teeth is the speed and quality of the dentin bridge formation, which will directly influence the long-term preservation of pulp vitality [15], as well as their mechanical

properties to provide fracture-resistant abutments supporting long-span prosthetic restorations [16]. Although calcium hydroxide allows the formation of a dentin bridge, the resulting osteodentin has a rather porous structure, favoring pulp infection and/or necrosis [17]. Biodentine™, through the chemical setting reaction of its two main components (tricalcium silicate= Ca_3SiO_5 and dicalcium silicate= Ca_2SiO_4) also acts through the release of calcium hydroxide. However the

dentin bridge formation in Biodentine™ treated cavities is more homogenous than with the calcium hydroxide-based materials [18, 19]. The mineralized tissue formation under Biodentine™ is accompanied by expression of odontoblastic markers [20] and seem to be mainly triggered by TGF-β1 growth factor release from pulp cells. This factor attracts pulp stem cells to Biodentine™ application site, where it induces their differentiation into odontoblastic cells secreting reparative dentin [21].

Biodentine™ also presents enhanced sealing abilities and mechanical properties which are very similar to those of dentin (elastic modulus of 22 GPa, compressive strength of 220 MPa and microhardness of 60 VHN) [11]. Another significant advantage is that several mechanical properties (such as compressive strength and shear bond strength of adhesives to Biodentine™) are not affected by restorative procedures, such as acid etching [22, 23]. This indicates that this material can be used in combination with resin composites as filling materials or with resin-based luting cements in cases where all ceramic restorations are the treatment of choice. Moreover, the ability of the material to create a firm bond with the underlying dentin substrate is highly required for core build-up materials, to ensure the preservation of the abutment integrity and

therefore to lower the risk for crown or bridges detachment. Although the material can exert its bioactive action within a period of six weeks, allowing then for the placement of the definite restoration (filling, crown, etc), in cases of a questionable pulp status, the material can be kept in situ as a bulk filling material for up to six months. During this period, the material preserves acceptable surface properties regarding anatomic form, marginal adaptation and interproximal contact [8]. This is of high importance for the evaluation of vital strategic abutment teeth that will be used underneath long-span prosthetic restorations. Overall, these properties seem to be very promising for its use as a universal core-build up material of vital abutment teeth. In conclusion, application of Biodentine™ for a period of 6 weeks is a promising treatment modality to maintain pulp vitality of prosthetic abutments after removal of deep caries. Its unique set of handling, mechanical and biological properties are highly desirable for a dentin substitute in restorative dentistry and prosthodontics. Randomized control clinical trials will be able to validate its use as a material of choice for abutment build-up in Prosthodontics, especially in teeth that serve as terminal abutments of long-span restorations that are normally subjected to high masticatory forces.



Author: Dr. Athina Bakopoulou

Lecturer at the Department of Fixed and Implant Prosthodontics at the School of Dentistry of the Aristotle University of Thessaloniki. Since 2009 she is a Visiting Research Fellow at the Department of Conservative Dentistry, Periodontology and Preventive Dentistry of the Center of Oral and Maxillofacial Sciences of the Hannover Medical School in Germany. She graduated from the National and Kapodistrian University of Athens in 2000 and subsequently followed a 3-year postgraduate program in Prosthodontics (2001-2004) and a 3-year PhD program (2004-2007) at the University of Thessaloniki. She has already significant published work in peer-review journals in the field of prosthetic rehabilitation, biocompatibility of dental restorative materials and dental tissue engineering and she has presented her research and clinical work in more than 50 international and national meetings and conferences, where she has been the recipient of significant awards, including the first award for “outstanding poster presentation” at the 11th (Crete, Greece, 2005) and the 12th (Fukuoka, Japan, 2007) Biannual Meeting of the International College of Prosthodontists (ICP), as well as the first Senior Robert Frank Award for Basic Research at the 44th IADR-CED Meeting (Munich, Germany, 2009).

References

01. Sailer I, Pjetursson BE, Zwahlen M, Hämmerle CH. A systematic review of the survival and complication rates of all-ceramic and metal-ceramic reconstructions after an observation period of at least 3 years. Part II: Fixed dental prostheses. *Clin Oral Implants Res* 2007;18Suppl 3:86-96.
02. De Backer H, Van Maele G, De Moor N, Berghe L. Long-term results of short-span versus long-span fixed dental prostheses: an up to 20-year retrospective study. *Int J Prosthodont* 2008;21:75-85.
03. Fransson H. On the repair of the dentine barrier. *Swed Dent J Suppl.* 2012;(226):9-84
04. Al-Hiyasat AS, Barrieshi-Nusair KM, Al-Omari MA. The radiographic outcomes of direct pulp-capping procedures performed by dental students. A retrospective study. *J Am Dent Assoc* 2006;137: 1699–1705.
05. Weiner RS, Weiner LK, Kugel G. Teaching the use of bases and liners: a survey of North American dental schools. *J Am Dent Assoc* 1996;127(11):1640-5.
06. da Silva LA, de Freitas AC, de Carvalho FK, de Queiroz AM, Nelson-Filho P, Porto-Neto ST. Direct pulp capping with a self-etching adhesive system: histopathologic evaluation in dogs' teeth. *Oral Surg Oral Med Oral Pathol Oral Radiol Endod* 2009;108(1):34-40.
07. de Souza Costa CA, Teixeira HM, Lopes do Nascimento AB, Hebling J. Biocompatibility of resin-based dental materials applied as liners in deep cavities prepared in human teeth. *J Biomed Mater Res B Appl Biomater* 2007;81(1):175-84.
08. Koubi G, Colon P, Franquin JC, Hartmann A, Richard G, Faure MO, Lambert G. Clinical evaluation of the performance and safety of a new dentine substitute, Biodentine™, in the restoration of posterior teeth - a prospective study. *Clin Oral Investig* 2013;17(1):243-9.
09. Camilleri J, Sorrentino F, Damidot D. Investigation of the hydration and bioactivity of radiopacified tricalcium silicate cement, Biodentine™ and MTA Angelus. *Dent Mater* 2013;29(5):580-93.
10. Shayegan A, Jurysta C, Atash R, Petein M, Abbeele AV. Biodentine™ used as a pulp-capping agent in primary pig teeth. *Pediatr Dent* 2012;34(7):e202-8.
11. Grech L, Mallia B, Camilleri J. Investigation of the physical properties of tricalcium silicate cement-based root-end filling materials. *Dent Mater* 2013;29(2):20-8.
12. Zanini M, Sautier JM, Berdal A, Simon S. Biodentine™ induces immortalized murine pulp cell differentiation into odontoblast-like cells and stimulates biomineralization. *J Endod* 2012;38(9):1220-6.
13. Stober T, Rammelsberg P. The failure rate of adhesively retained composite core build-ups in comparison with metal-added glass ionomer core build-ups. *J Dent* 2005;33(1):27-32.
14. Sterzenbach G, Karajouli G, Naumann M, Peroz I, Bitter K. Fiber post placement with core build-up materials or resin cements-an evaluation of different adhesive approaches. *Acta Odontol Scand* 2012;70(5):368-76.
15. Leye Benoist F, Gaye Ndiaye F, Kane AW, Benoist HM, Farge P. Evaluation of mineral trioxide aggregate (MTA) versus calcium hydroxide cement (Dycal®) in the formation of a dentine bridge: a randomised controlled trial. *Int Dent J* 2012;62(1):33-9.
16. Theodosopoulou JN, Chochlidakis KM. A systematic review of dowel (post) and core materials and systems. *J Prosthodont* 2009;18(6):464-72.
17. Mohammadi Z, Dummer PM. Properties and applications of calcium hydroxide in endodontics and dental traumatology. *Int Endod J* 2011;44(8):697-730.
18. Tran XV, Gorin C, Willig C, Baroukh B, Pellat B, Decup F, Opsahl Vital S, Chaussain C, Boukpepsi T. Effect of a calcium-silicate-based restorative cement on pulp repair. *J Dent Res.* 2012;91(12):1166-71.
19. Gandolfi MG, Ciapetti G, Perut F, Taddei P, Modena E, Rossi PL, Prati C. Biomimetic calcium-silicate cements aged in simulated body solutions. Osteoblast response and analyses of apatite coating. *J Appl Biomater Biomech* 2009;7(3):160-70.
20. Laurent P, Camps J, About I. Biodentine™ induces TGF-β1 release from human pulp cells and early dental pulp mineralization. *Int Endod J* 2012;45(5):439-48.
21. Mathieu S, Jeanneau C, Sheibat-Othman N, Kalaji N, Fessi H, About I. Usefulness of Controlled Release of Growth Factors in Investigating the Early Events of Dentine-pulp Regeneration. *J Endod* 2013;39(2):228-35.
22. Kayahan MB, Nekoofar MH, McCann A, Sunay H, Kaptan RF, Meraji N, Dummer PM. Effect of Acid Etching Procedures on the Compressive Strength of 4 Calcium Silicate-based Endodontic Cements. *J Endod* 2013;39(12):1646-8.
23. Odabas ME, Bani M, Tirali RE. Shear bond strengths of different adhesive systems to Biodentine™. *Scientific World Journal* 2013:626103. doi: 10.1155/2013/626103.

β -TCP (R.T.R.) and aggressive periodontitis

Djamila BOUZIANE - Professor, University of Oran, Algeria

Khadidja L. MAKRELOUF - Professor, University of Oran, Algeria

Mohamed BOUZIANE - Professor, University of Oran, Algeria

We have not found in the international literature any study regarding the use of β -TCP in the treatment of infrabony pockets in young patients with aggressive periodontitis, which are a clinical entity that very rapidly results in the destruction of alveolar bone with tooth morbidity as a consequence. For this reason the objective of this study is to evaluate and analyse the action of β -TCP (R.T.R.) on infrabony lesions in young patients suffering from aggressive periodontitis.

Introduction

Aggressive periodontitis, a clinical case frequent in the Maghreb, represents the most destructive form of periodontal diseases which results in bone lysis, dental mobility and then loss of teeth. Their appearance starts early in life causing aesthetic and functional damage.

These diseases are characterised by a anaerobic Gram negative flora.

There are two classes:

- The form localised in the incisors and the first molars, as shown clinically in Figure 1 and with X-ray in Figure 2.

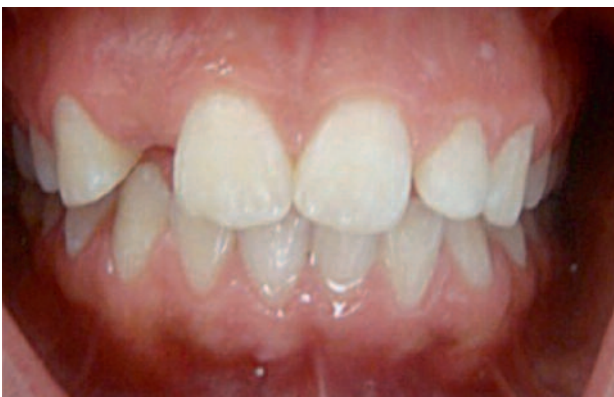

Fig. 1: Clinical aspect

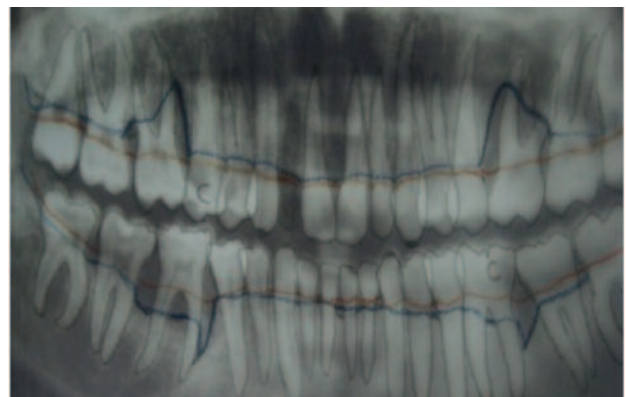


Fig. 2: Notice the terminal lysis at the level of 21

- The form generalised to the entire dentition (Fig. 3 & 4).

The size of the bone lesions requires a well targeted therapeutic strategy.

The objective of our work is to choose sites at the level of the upper or lower incisors and first molars of patients suffering from aggressive periodontitis with pockets deeper than 5 mm, infrabony defects that allow the insertion of β -TCP (R.T.R.). We will test the influence and impact of this substitute material on bone behaviour.

Materials & methods

We perform on each patient a clinical, radiological and bacteriological examination followed by a surgical treatment consisting in flap surgery combined with R.T.R. grafting material (syringe). The clinical evaluation consisted in measuring the depth of the pockets.

The X-ray examination allowed the evaluation of the bone level of our patients thanks to the retroalveolar - panoramic and radiovisiography images. The bacteriological evaluation consisted in subgingival specimens and fresh bacterial profile study, Gram staining, culture and PCR.

The therapeutic schedule consisted in:

- Initial therapy (scaling and root planing)
- A systemic anti-infectious therapy with amoxicillin 1 g/d and metronidazole 600 to 800 mg/d over 10 days.
- A surgical therapy combining flap surgery and insertion of R.T.R.
- The surgical sequence is the following:
 - Anaesthesia
 - Incisions
 - Careful debridement
 - Elimination of granulation tissue
 - Scaling and root planing
 - In situ placement of R.T.R. using the syringe presentation
 - Sutures
 - Placement of surgical pack
 - A maintenance phase with clinical and radiography re-assessments over four years

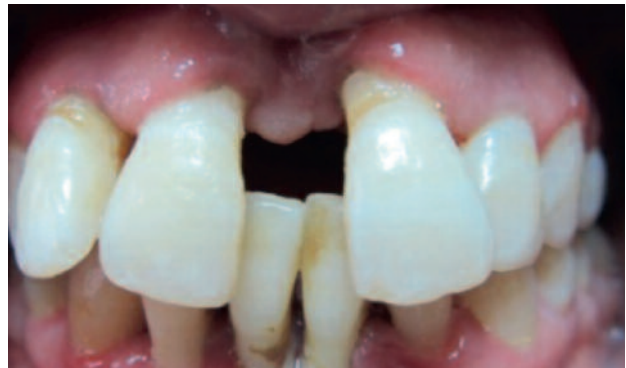

Fig. 3: Inflammatory aspect

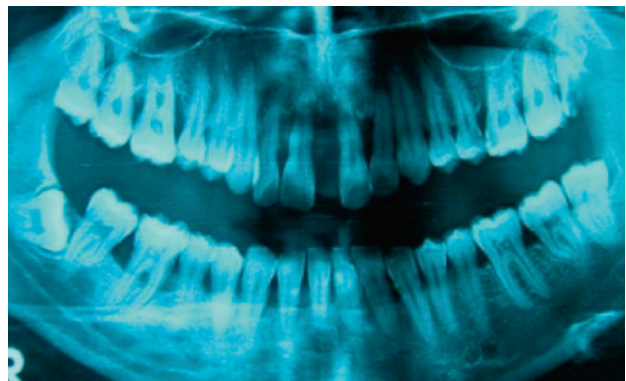


Fig. 4: Terminal lysis at 21 and 11

Case series

4 patients were chosen for whom five sites were treated:

- 2 upper sites (16-21)
 - 3 lower sites (36-46-46)
- The first patient presented a generalised aggressive periodontitis with a severe intrabony defect at 21 associated with an extrusion and at the level of 16 a terminal bone lysis with a pocket depth of 9 mm.
 - The second patient suffered from generalised aggressive periodontitis with class 3 bifurcation involvement at the level of 46 as well as mesial and distal pocket depth of 7 to 5 mm.
 - The third patient, 17 years old, with localised aggressive periodontitis and mesial infrabony lesions with a pocket depth of 8 mm.
 - The fourth patient, 16 years old, with a localised aggressive periodontitis, presented 5 mm pockets distally at the level of 46.

Case Report no.1

A 19-year-old woman presented with severe generalised aggressive periodontitis.

On a clinical level, this patient presented an inflammatory condition of the maxillary and mandibular gum with migration of 21 (*Fig. 5*).

On a radiographic level, the panoramic X-ray of the maxillary showed infrabony lesions (*Fig. 6*) with deep lysis at the level of 21 and terminal lysis at the level of 16 (*Fig. 7*).

It was decided to treat 21 and 16 given the situation of these severe lesions.

The therapeutic schedule adopted is the following at the level of 21.

T0

- Etiological therapy + amoxicillin + metronidazole antibiotic therapy
- Surgical phase: flap + bone substitute: R.T.R. (*Fig. 8 & 9*)

T 1 year

- Clinical and X-ray reassessment. On the X-ray, filling of infrabony lesion with 25% bone gain. (*Fig. 10*)
- At this stage the migration treatment was performed.
- Orthodontic treatment phase due to migration of 21 (*Fig. 11*)

A stabilisation of the bone gain after initiation of orthodontic treatment was observed (*Fig. 12*)

The reassessment of the infrabony lesion at 4 years by radiovisiography showed a bone gain of 50% (*Fig. 13*). A definitive fixation was performed.

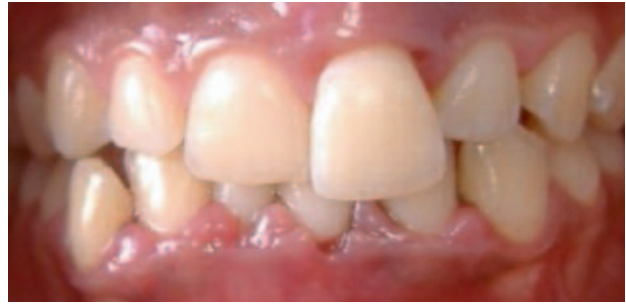

Fig. 5: Clinical inflammatory aspect

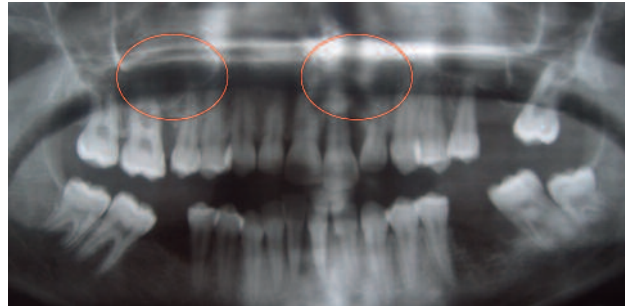


Fig. 6: X-ray :Generalised lysis at the level of the maxillary

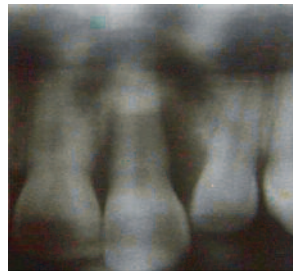


Fig. 7: Severe infrabony defect at the level of 21

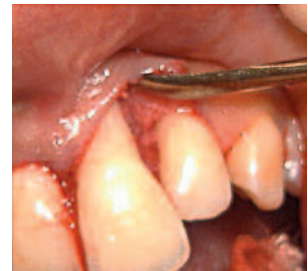

Fig. 8: Incisions - raising of a flap

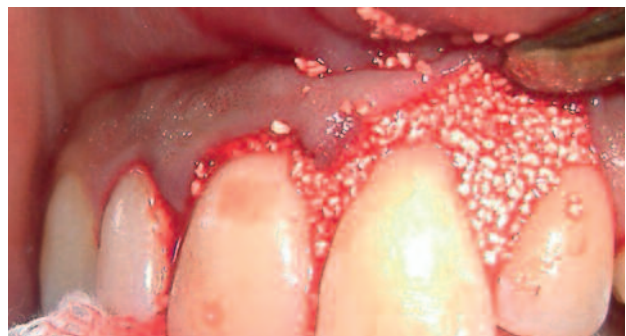

Fig. 9: Insertion of bone substitute

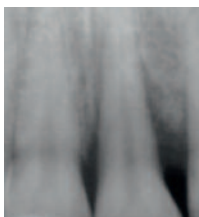

Fig. 10: Result at 1 year

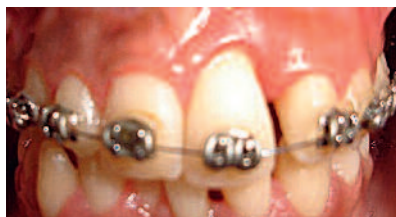

Fig. 11: DFO treatment of migration at 1 year

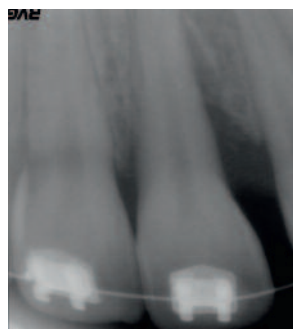


Fig. 12: Stabilisation of bone gain

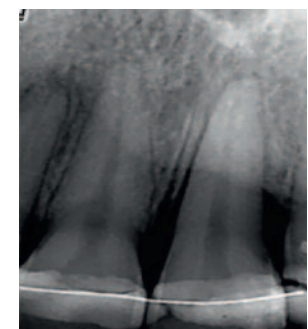


Fig. 13: RVG 50% bone gain at 4 years

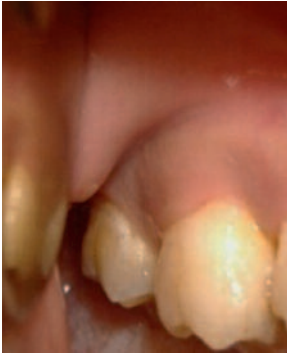

Fig. 14: Clinical aspect

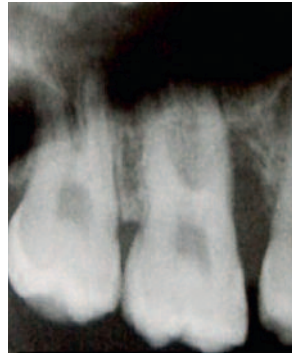

Fig. 15: Terminal lysis

The study of the posterior site (16) in the same patient showed:

- On a clinical level, the probing detected pocket depths of 9 to 11 mm (Fig. 14).
- On the X-ray, a terminal bone lysis (Fig. 15).

The therapeutic schedule of the infrabony lesion of 16 is the following:

- Etiological therapy
- Surgical phase: mucoperiosteal flap associated with in situ placement of R.T.R.

The surgical treatment sequence:

- Incision and raising of the flap (Fig. 16)
- Debridement of lesion
- Elimination of granulation tissue
- Polishing and planing of root
- Insertion of R.T.R. using the syringe: the granules are mixed with a few drops of blood (Fig. 17)
- Sutures
- Surgical pack (Fig. 18)
- Placement of surgical pack

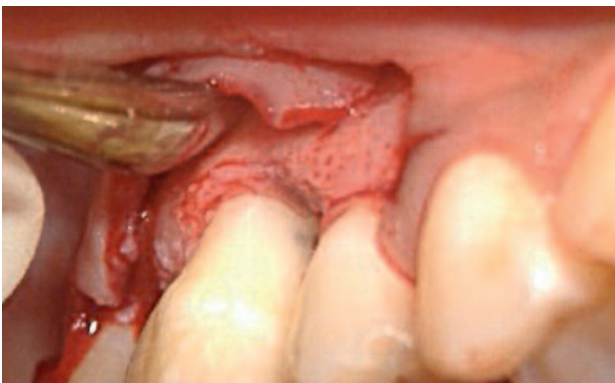

Fig. 16: Incision and raising of flap

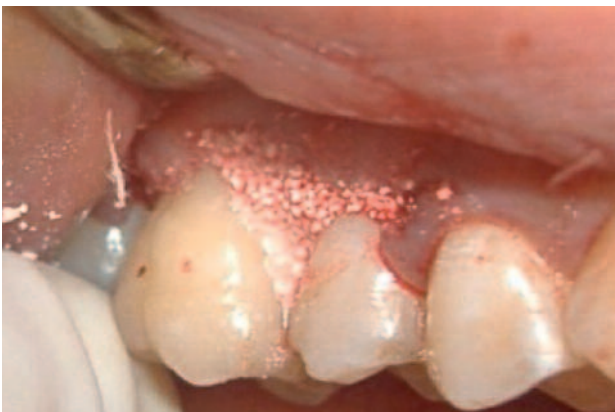

Fig. 17: In situ placement of R.T.R.

The reassessment at 1 year shows the filling of the infrabony lesion (Fig. 19).

At 4 years it shows a 50% bone gain (Fig. 20).

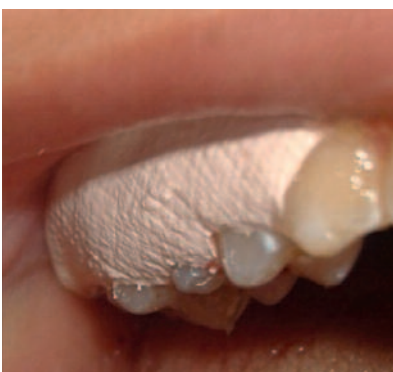

Fig. 18: Surgical pack

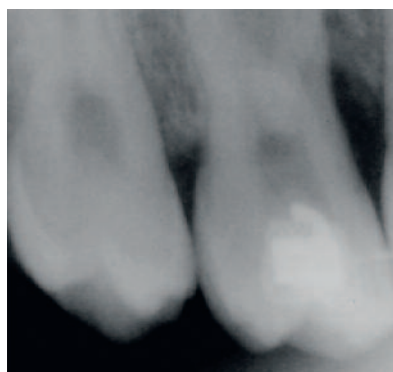

Fig. 19: At 1 year

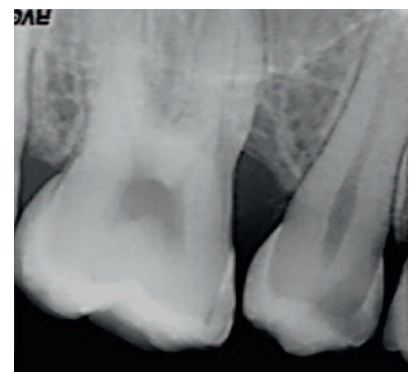


Fig. 20: At 4 years

Case Report no.2

A 18-year-old patient presented with severe generalised aggressive periodontitis (*Fig. 21*). The panoramic x-ray showed at the level of 46: Infrabony lesion + bifurcation involvement and depth of pockets of 7 mm (*Fig. 22*).

Clinical aspect before surgery (*Fig. 23*). Placement of R.T.R. (*Fig. 24*).

The radiography X-ray shows an infrabony lesion associated with a class 3 bifurcation involvement (*Fig. 25*). At 15 days the filling material is in place (*Fig. 26*).

At 4 years the reduction in the pocket depth is of 4 mm, we noticed the absence of bifurcation involvement (*Fig. 27*).

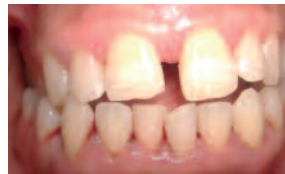

Fig. 21: Clinical aspect

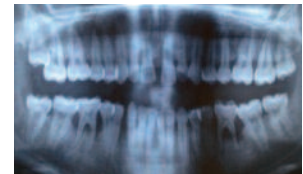


Fig. 22: Class 3 bifurcation

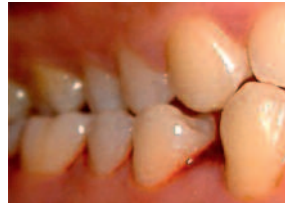

Fig. 23: Clinical aspect

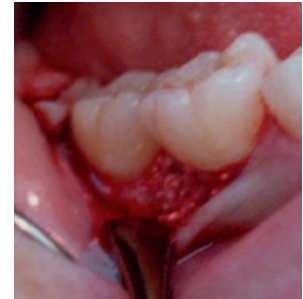

Fig. 24: Placement of R.T.R.

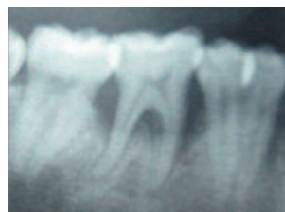

Fig. 25: Before treatment

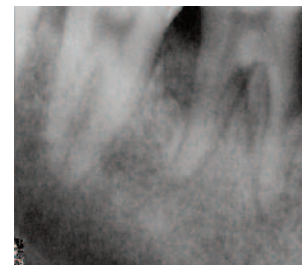


Fig. 26: 15 days after the filling

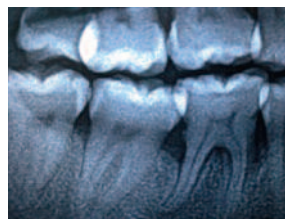


Fig. 27: Result at 4 years

Case Report no.3

A 17-year-old patient presented with localised aggressive periodontitis (*Fig. 28*) with an average pocket depth of 8 mm and mesial infrabony lesion of 36 (*Fig. 29*).

The therapeutic schedule is the following:

- Etiological therapy associated with medical treatment which consisted in a combination of amoxicillin and metronidazole during 10 days
- Surgical treatment: incision (*Fig. 30*), raising of the flap, placement of the bone substitute (*Fig. 31*).

The results at 1 year (*Fig. 32*) and at 4 years (*Fig. 33*) are very satisfactory.

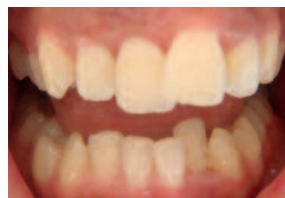

Fig. 28: Clinical aspect

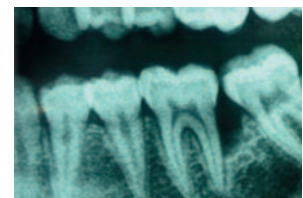


Fig. 29: Deep lysis

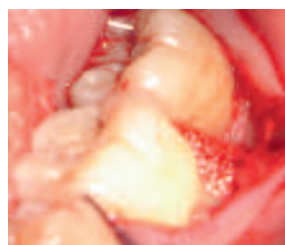

Fig. 30: Placement of R.T.R.

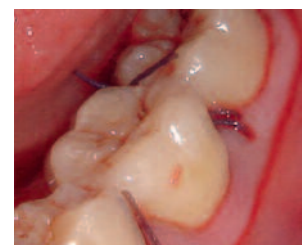

Fig. 31: Sutures

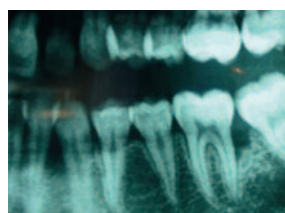


Fig. 32: At 1 year

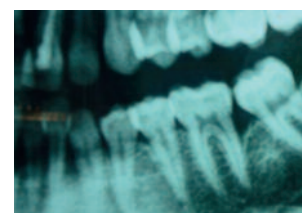


Fig. 33: At 4 years

Case Report no.4

The 16-year-old patient presented with inflammatory gum condition (*Fig. 34*). In the X-ray, we observed prior to treatment an infrabony defect of 46 with a pocket depth of 5 mm and 25% bone loss (*Fig. 35*).

For this patient, it was decided to follow the same therapeutical protocol as previously described.

At 4 years we see the filling of the infrabony lesion with an absence of periodontal pocket and a normal aspect of the desmodontal space (*Fig. 36*).

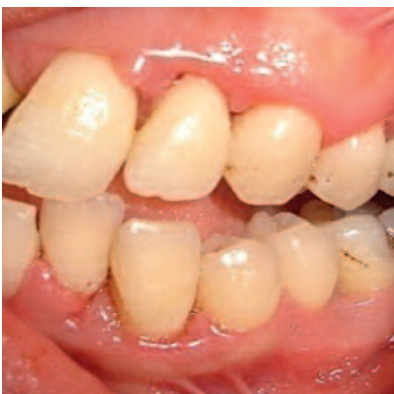

Fig. 34: Clinical aspect

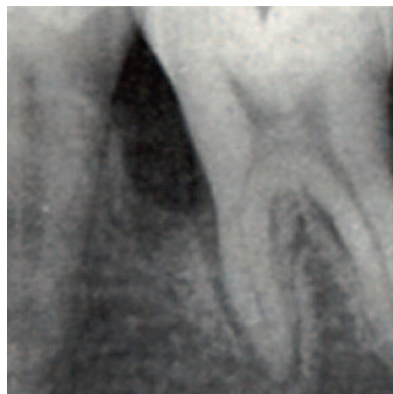

Fig. 35: Infrabony defect before treatment

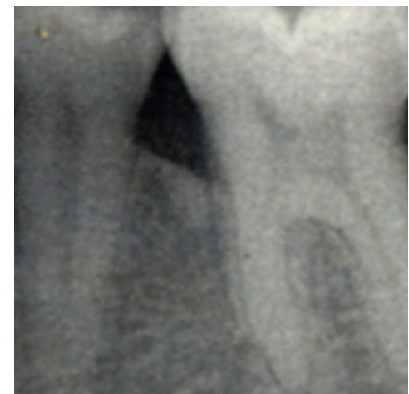

Fig. 36: Bone repair

Discussion

The use of R.T.R. (β -TCP) allowed:

- A reduction in the depth of pockets and an attachment gain.
- A decrease in the dental mobility index.
- The panoramic and the visiography X-rays showed a bone gain with filling of infrabony lesions.
- Modifications of the bacterial biofilm in numerous studies (Haffajee and al.) show that certain species of the red complex (*Tannerella forsythus*, *Treponema denticola*) and of the orange complex (*Prevotella intermedia*, *Campylobacter rectus*) can evolve differently. Depending on the surgical debridement, these species can recolonise the sites in a very delayed manner due to the decrease in their

toxic potential and the modification of their tissue environment.

We thus observed in our patients a decrease in bacteria such as *Tannerella forsythus*, *Prevotella intermedia*, *Porphyromona gingivalis*, *Aggregatibacterium actinomycetemcomitans*, *Treponema denticola* at 1 year and 4 years.

The flap combined with the filling would be in favour of the restoration of the epithelial barrier at the bottom of the pocket with an almost absence of the available nutrients essential for the red and orange complex bacteria.

- The bone gain obtained would be related to the use of phosphocalcium derivative bioactive materials which increase bone formation.

Conclusion

Our work demonstrates that an advanced aggressive periodontitis with the presence of terminal lysis could be currently treated whereas about fifteen years ago tooth extraction was the only alternative.

A significant improvement of the depth of the pockets, attachment level, decrease in dental mobility, modification of subgingival bacterial biofilm and bone gain are the results obtained at 4 years.

The success of our therapy would not have been possible without fighting against the bacterial biofilm, or without the full cooperation and consent of our patients.

These diseases constitute a public health problem due to the speed and severity of their evolution with functional consequences and psychosocial repercussions related to the early loss of teeth. This technique has given excellent results in young subjects.

Authors



Prof. Djamila Bouziane: University Hospital Professor (University of Oran/Oran University Hospital) - Head of Department of Periodontology - Head of Department of Dental Surgery - President of the scientific council of the health research topic agency - President of the national dental medicine teaching committee - President of the regional speciality teaching committee (Parodontology) - President of the national speciality teaching committee (Periodontology) - Director of the oral biology laboratory - Member of the scientific council of the Oran university academy - ANDRS expert (National

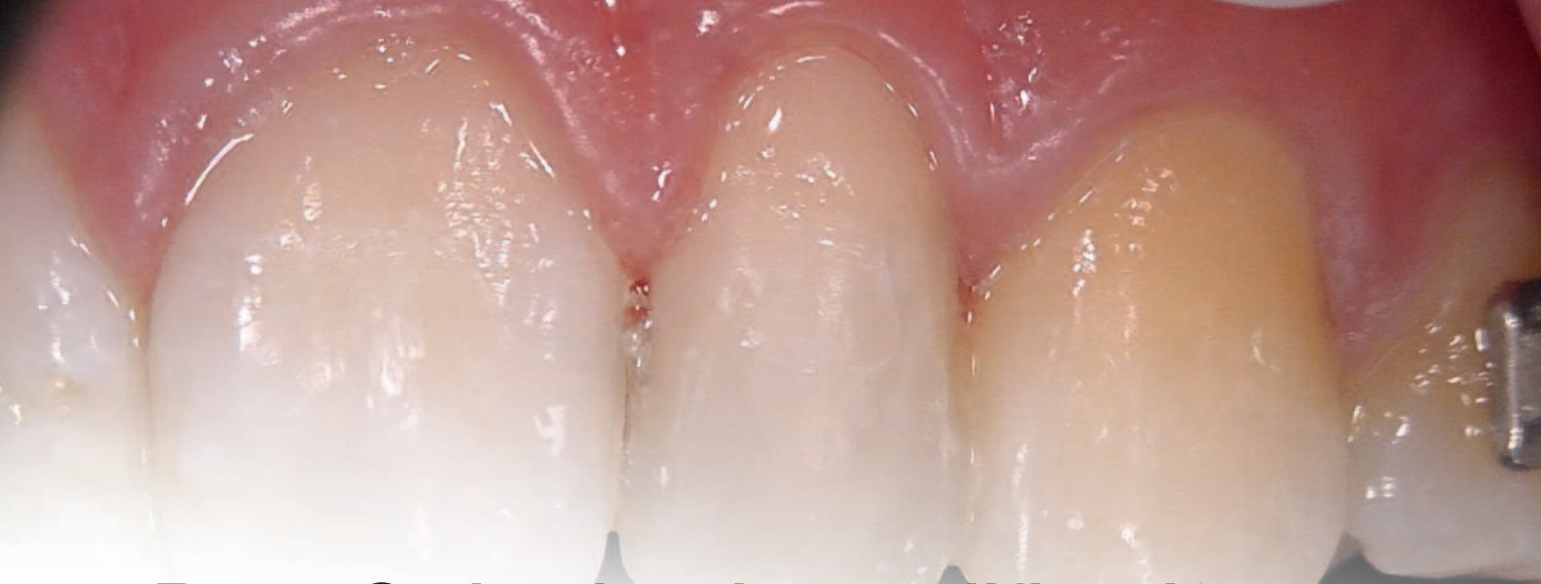
Agency for the development of health research) in charge of building a national health research program - Founder and President of the Société Algérienne de Médecine Dentaire (SAMD, Algerian Dental Medicine society) - Member of the Société Algérienne d'Odontologie Pédiatrique (SAOP, Algerian Paediatric Odontology Society) - Member of the National Dental Committee - Vice-President of the International Conference of French language Deans - Member of the Académie Française de Chirurgie Dentaire (ANCD, French Academy of Dental Surgery) - Leader of numerous research projects.

Mohamed Bouziane: University Hospital Professor (University of Oran/Oran University Hospital) - Head of Department of Prosthetics.

Leila Khadidja Makrelouf: University Hospital Professor (Periodontology) (University of Oran/Oran University Hospital).

References

01. ANAGNOSTOU F., OUHAYOUN J.P. Valeur biologique et nouvelle orientation dans l'utilisation des matériaux de substitution osseuse. *J parodontologie et implantologie orale* 19.317-243 2000
02. BAEHNI P.C., GUGGENHEIM B. (1999). Potential of diagnostic microbiology for treatment and prognosis of dental caries and periodontal diseases. *Crit Rev Oral Biol Med.* 7(3):259-277(1996).
03. BARSOTTI O., BONNAURE-MALLET M., CHARIN H., CUISINIER F., MORRIER J.J., ROGER LEROY V. Tests biologiques en odontologie. *Dossiers ADF edit SAGIM-CANALE* 6-60-2007.
04. BOUZIANE D. Conférence épidémiologie analytique et prise en charge des parodontites juvéniles. Symposium sur les parodontites agressives de l'enfant et du jeune adulte. Société Française de parodontologie et Académie internationale de parodontologie - Marrakech 01 Juin 2001
05. CHARDIN H., BARSOTTI O., BONNAURE-MALLET M. *Microbiologie en Odonto Stomatologie Edit Maloine* 2006.
06. CHARON J.A., SANDELÉ P., JOACHIM F. Conséquences pratiques des nouveaux moyens de diagnostic en parodontie *Inf. Dent. M.* 5 (12) 873-883-1993.
07. GIBERT P., TRAMINI P., BOUSQUAT P. H., MARSAL P. Produits antibactériens d'usage local en parodontie *AOS n° 212 : 455-465-décembre* 2000.
08. HAFFAJEE A.D., TELES R.P., SOCRANSKY S.S. The effect of periodontal therapy on the composition of the subgingivalmicrobiota. *J. Periodontol* 2000, 42: 219-258-2006.
09. M. LABANCA and Coll. Biomaterials for bone regeneration in oral surgery: A multicenter study to evaluate the clinical application of "R.T.R." *Case studies Collection n°7: 4-11 Mars* 2014
10. O.H. ARRIBASPLATA LOCONI. Bone regeneration with β -tricalcium phosphate (R.T.R.) in post-extraction sockets. *Case studies Collection n°7: 12-20 Mars* 2014
11. MATTOUT P., MATTOUT C. Les thérapeutiques parodontales et implantaires *Quintessence Inter* 2003.
12. MICHEAU C., KERNER S., JAKMAKJIAN S. Intérêt du phosphate tricalcique β en parodontologie et implantologie. *Le Chirurgien Dentiste de France: 1308 : 31-38-2007*
13. PRINC G., BERT M., SZABO C. Utilisation de substitut osseux β -phosphate tricalcique. *Etude préliminaire. CDF, 2001 ; 1055 : 29-34*
14. PRINC G., BERT M., IFI J.C. Utilisation du substitut osseux β -phosphat tricalcique (β -TCP résultats a 3 ans) *Le Chirurgien dentiste de France* 1250/1251/23-30 Mars 2006
15. SIXOU M., DUFFAUT D., LODTER JP. Distribution and prevalence of *Haemophilus actinomycetemcomitans* in the oral cavity. *J. BiolBuccal* 19: 221-228-1991.
16. SOCRANSKY S.S., HAFFAJEE A.D. The bacterial etiology of destructive periodontal diseases: current concepts. *J. Periodontol* 63: 322-331-1992.
17. TENNE BAUME H. Les matériaux de substitutions osseuses. *Dossier ADF - Edit SAGIM CANALE: 5-49-2005.*
18. VAN WINKELHOFF A.J. et WINKEL E.G. Microbiological diagnostics in periodontics: biological significance and clinical validity *Periodontology* 2000, Vol. 39: 40-52-2005.



Post-Orthodontic modification of aesthetics with N'Durance[®]: the “fingertip technique”

Christina BOUTSIUKI, DDS and Prof. Paris Gerasimou
Department of Operative Dentistry
Aristotle University of Thessaloniki, Greece

Introduction

A multidisciplinary approach is often needed in order to improve aesthetics and orthodontic therapy is often combined with minimal aesthetic interventions. Alterations in tooth shape and size result in impaired esthetic appearance and facial harmony and can have a negative effect on a young patient's self-esteem, after orthodontic treatment. Aesthetic appearance and “cure-on-command” features have made photopolymerizable dimethacrylate-based composites a popular choice over numerous

other materials for use in aesthetic dental restorations. Evolution of adhesion has given composite resin restorations the opportunity to be regarded as minimally invasive treatments or even no-prep restorations. Thus, healthy dental tissues are protected and invasive options, like crowns or veneers, are still available in the future at patient's wish. Due to its longevity (Scarpelli et al. 2008), treatment with composite resin is regarded as a well-established alternative.

The techniques of Aesthetics with composites

In order to create a composite resin restoration that cannot be distinguished practically from the natural tooth, a composite system is needed which offers shade levelling, as well as variety in translucency, allowing for individual optical effects and generation of natural anatomical

characteristics. Aesthetically demanding anterior restorations, such as build-up of a peg-shaped lateral, is ideally performed with the “incremental”, “polychromatic” or “layering technique”. All of these terms are used to describe the successive placement of composite resin incre-

ments of different shades, in order to finally mimic the natural tooth structure. Layering can be achieved both by building incrementally from inner towards the outer tooth surface or vice versa. The first option, building from inner towards the outer surface, is done free-hand, therefore demanding a high level of practice and expertise. Composite resin mimicking the dentinal shade is chosen and is placed as a core, followed by the labial and palatal placement of the enamel shade, which are usually more translucent. Building an anterior tooth from the outer surface towards the inner, is more simple, but a silicon key is needed as a guide, therefore an extra process of intraoral mock-up or impression taking and diagnostic wax-up, is needed. The main idea behind this technique is that the silicon key is used as guidance in order to build the palatal surface, and consequently the palatal surface is used as a guide for the rest of the increments. Alternatively, in order to simplify the clinical procedure, the “fingertip technique”, which is described in this article, can replace the need of a silicon key. Palatal enamel shade is placed first, followed by dentine shade, and finally

labial enamel shade. Once the clinician gets familiar with layering, variations of these techniques can also be used, such as the “cut-back” technique, at which microstructure is created by using a diamond bur on a monochromatic dental core to roughly form lobes, mamelons, marginal ridges etc, and then enamel shade and tints or opalescence at an advanced level of expertise, are added to create a final, smooth appearance. With layering techniques, it is important to keep in mind that, besides choosing the correct shades, success of the finished restoration depends on the layer thickness ratio of opaque and translucent shades. Translucency should be used sparingly, in order to avoid a gray undertone in the final restoration, putting patient age into consideration. When selecting the translucent enamel shade, clinicians must keep in mind that enamel transparency tends to increase overtime. The enamel layer must, therefore, be approximately 0.2-1 mm thick, according to the area of the tooth and patient age. Last but not least, polishing is an important parameter in achieving the final lustre of the restoration and maintaining the aesthetic results longer.

Composite Resins

Composite resin systems consist of many different shades and translucencies for fabricating aesthetic restorations, requiring plenty of experience. In order to find the correct composite resin shade, the basic hue (A, B, C or D) and chroma (A1, A2 or A3) should be chosen. Shade guide should be made of composite material and should match exactly to the chosen shade after polymerization. In case shade match is performed by placing a piece of composite directly on the tooth surface, material should be polymerized first. It should be noted that composite resin shades could be altered following polymerization. While microfilled resins become lighter (greater value and lower chroma), micro-hybrid products become darker (lower value and higher chroma). Polishability and other

optical characteristics depend on composite resin's inorganic particles, the fillers. Long-term maintenance of the restoration is also connected to physical and mechanical characteristics, paying special attention to monomer conversion, which reflects the amount of composite resin which has been properly polymerized, and depends on monomer type, type of light source, power of curing device, curing time etc. Despite the fact that composite resin surface is hard after curing, final double bond conversion can reach 75% (60% after filler addition). Dimer-acid base monomer (DDCDMA) technology results in higher monomer conversion (83% or 75% after filler addition) and therefore lower water uptake, achieving long-term maintenance of the restoration.

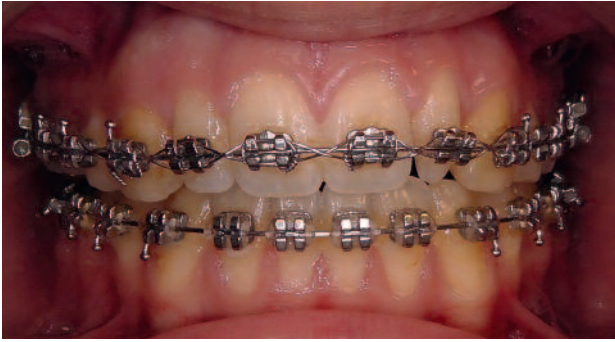

Fig. 1: Clinical image at the end of orthodontic therapy

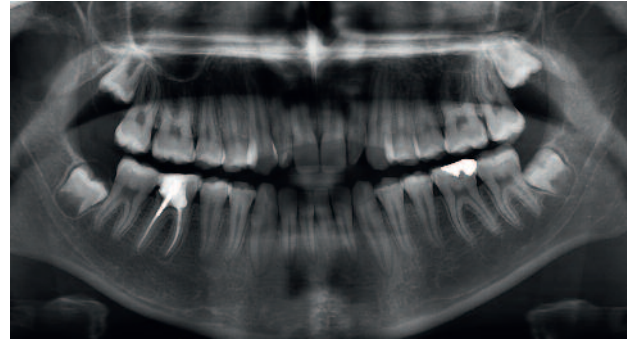


Fig. 2: Radiographical image in order to check for supernumerary maxillary teeth or missing premolars, usually accompanying peg-shaped laterals. It was confirmed that the peg-shaped tooth was a lateral and not a canine or a supernumerary tooth

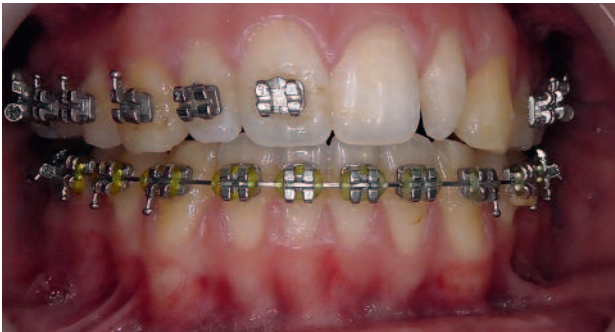

Fig. 3: Brackets were removed from the peg-shaped lateral and adjacent teeth

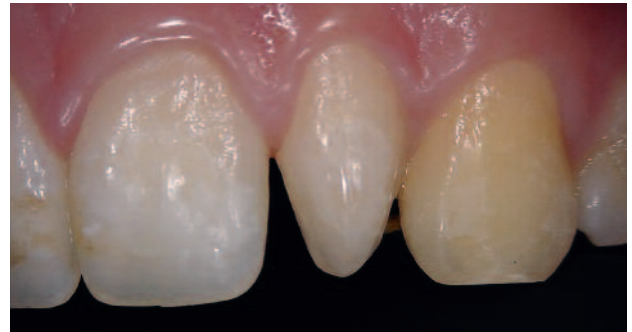

Fig. 4: Clinical image after polishing with a prophylaxis paste

Case Report

The following case represents the step-by-step procedure of a peg-shaped lateral incisor build-up with N'Durance®.

A 17-year-old female orthodontic patient, referred to the dental clinic with aesthetic concerns (*Fig. 1, 2*). Left lateral incisor was peg-shaped and an aesthetic intervention was asked, before the final corrections of the orthodontic alignment (*Fig.3*). Despite the fact that tooth size or shape disturbances are part of a complex of genetically related anomalies (Peck et al. 1996), no other clinical or radiographic evidence of accompanying anomaly was recorded. This shape alteration however, did not provide a uniform, aesthetic smile to the patient. From the smile-design point of view, it was noted that canine tips had been worn away but enamel at the incisal edge of the central incisors was evident. After clinical examination and discussion with the young patient and her mother, it was decided to choose a no-prep aesthetic restoration with N'Durance™.

No other treatment needs were recorded. Shade matching was performed with VITA shade-guide. Tooth shade was A3 at the cervical third and A2 at the middle and incisal third. The translucency at the incisal third of the neighboring teeth was also recorded. Due to the fact that the orthodontic mechanism exceeded to the palatal surfaces of her front teeth, no impressions could be made in order to follow the traditional way of diagnostic wax-up and silicon key. It was therefore decided to restore the tooth by means of the “fingertip technique”.

During the second visit, teeth were polished with a silicon point in order to remove any remnants from the bracket luting cement. Consequently, teeth were polished with a prophylaxis paste in order to achieve a clean surface (*Fig. 4*) and tooth shade was re-evaluated, resulting in the same choice. Rubber dam was placed and proximal surfaces of neighboring teeth were covered with PTFE tape before bonding proce-

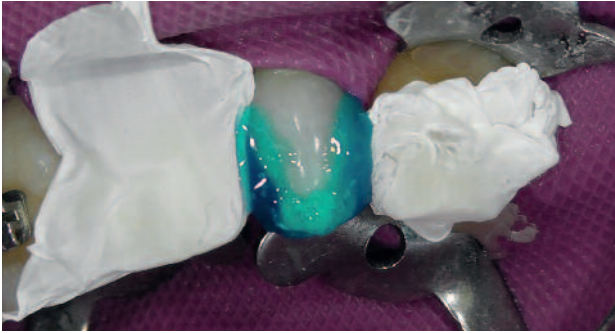

Fig. 5: PTFE tape placement in order to protect adjacent tooth surfaces from phosphoric acid during enamel etching

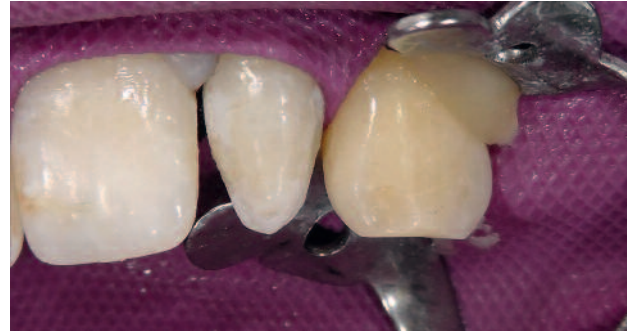

Fig. 6: Clinical image of etched enamel

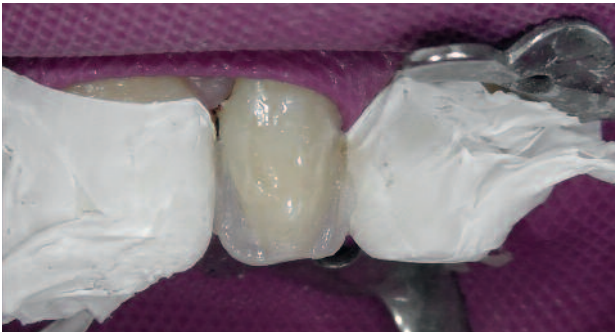

Fig. 7: Palatal enamel layer placed with the "fingertip technique"

dure. This was done in order to protect adjacent enamel from phosphoric acid. 37% phosphoric acid was placed on the peg-shaped lateral for 30" in order to etch enamel (*Fig. 5*). Phosphoric acid was continuously stirred with a dental explorer in order to eliminate bubble formation and achieve optimum enamel etching. Etchant was removed by means of water irrigation and high-power suction and enamel was air-dried (*Fig. 6*). New PTFE tape was placed on the proximal surfaces of the adjacent teeth in order to form a tight contact point and avoid adhesion. Bonding agent was applied in a thin layer on etched enamel, excess amount was blown with a slight air-breeze and was polymerized for 10" with a LED curing device. In order to reproduce the incisal translucency of the neighboring incisors, N'Durance® incisal shade was placed at the mesial and distal area of the peg-shaped lateral (*Fig. 7*), in order to create the external outline of the tooth and act as a supporting composite surface for the next steps. Due to the inability to produce a silicon key, composite was pressed palatally with the index fingertip, after the powder-free latex glove had been cleaned with alcohol (*Fig. 8*). Shade A2 was

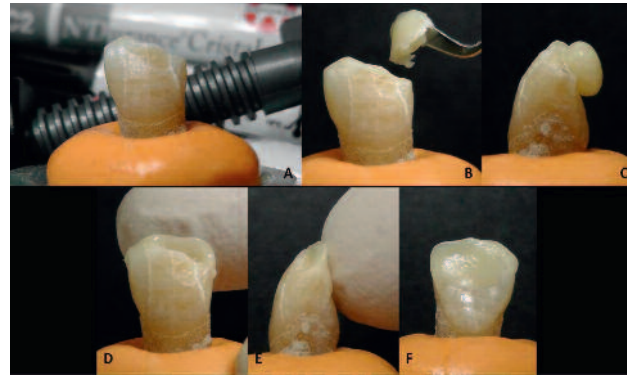


Fig. 8: The "fingertip technique" steps: A. Initial situation, B. Composite resin placement, C. Composite resin standing on the palatal surface, D. Piece of composite resin pressed against palatal surface with the index fingertip, E. Fingertip should always press against an existing tooth surface, in order to be able to create the correct palatal curvature at the composite resin, F. Final situation from the palatal side

used in order to form the dentinal lobes and was placed over the incisal shade, without covering the translucency completely at the incisal and proximal margins. Opaque shade was placed at the center of the restoration in order to accentuate the difference in translucency between the areas of the tooth and A3 was placed at the cervical third fading towards the center (*Fig. 9 and Fig. 10*). Finally, a thin enamel layer of the incisal shade was used in order to complete the restoration labially (*Fig. 11*). Restoration was finished with fine and ultra-fine polishing diamond burs and polishing was done with polishing discs of successive roughness and a diamond paste was used at the final step for achieving maximum gloss (*Fig. 12*). Immediate post-operative view exhibits the macromorphology of the restoration (*Fig. 13*) while next-day post-operative image shows the blending of the finished restoration with the rest teeth of the anterior aesthetic zone (*Fig. 14*). Orthodontic treatment continued as planned.

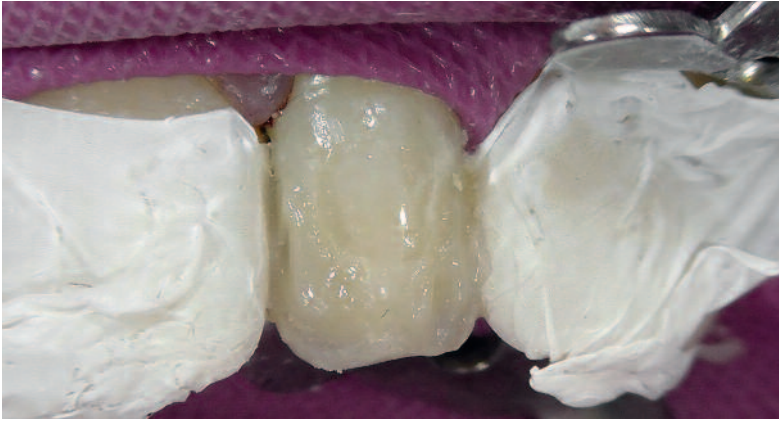

Fig. 9: Placement of shade A2 forming the dentinal lobes, opaque shade and A3 at the cervical area of the restoration

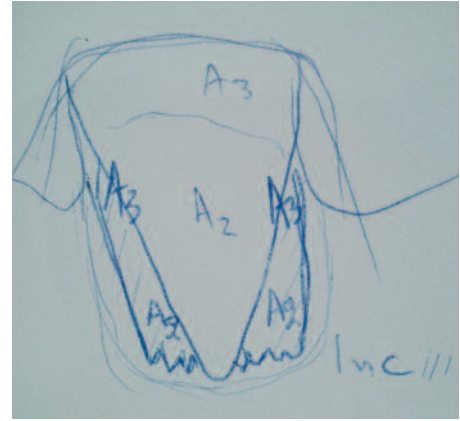


Fig. 10: Schematic drawing of shade placement

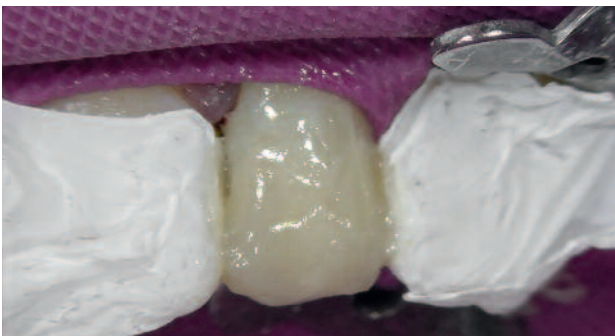

Fig. 11: N'Durance® incisal shade was placed labially to finish the restoration

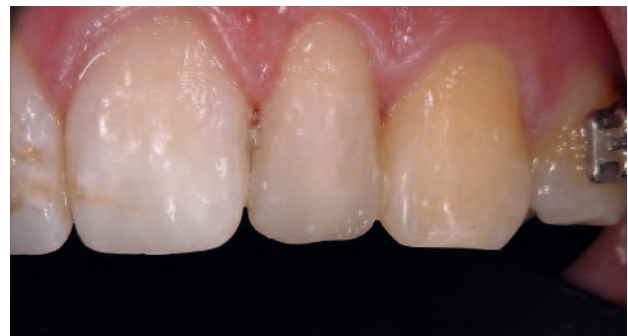

Fig. 12: Polished and finished restoration

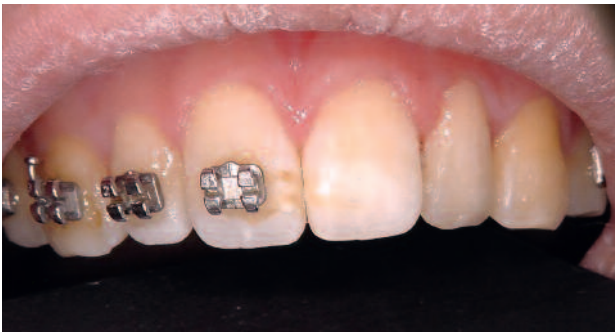

Fig. 13: Final clinical image

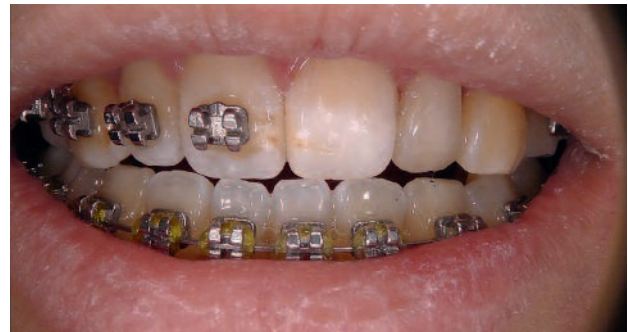

Fig. 14: Next-day post-operative clinical image

Conclusion

Orthodontic treatment alone, would not have given the patient the desired final outcome. Direct composite resin restorations, complementing orthodontic therapy, are minimally invasive, can be manufactured quickly, without the need of temporization or extra laboratory cost. In cases when no silicon key is available, extra time needed for intra-oral mock-up can be saved, by utilizing the “fingertip technique”.

Additionally, composite resins can be modified instantly intra-orally according to each patient’s wish. In order to create highly aesthetic smiles, layered technique should be used with easy-to-use composite resin systems with variable degree of translucency. Last but not least, besides restoring patient’s aesthetics it is also crucial to achieve a long-lasting and functional restoration.



Author: Dr C. Boutsiouki

Christina Boutsiouki graduated in 2011 and works as a general dentist. She is studying in the post-graduate MSc course in the Department of Operative Dentistry, in Aristotle University of Thessaloniki, Greece. Dr Boutsiouki is actively involved in research since 2008, focusing on dental materials, operative dentistry and pediatric dentistry. She participates in dental conferences and has published 23 scientific articles.

christinaboutsiouki@gmail.com

References

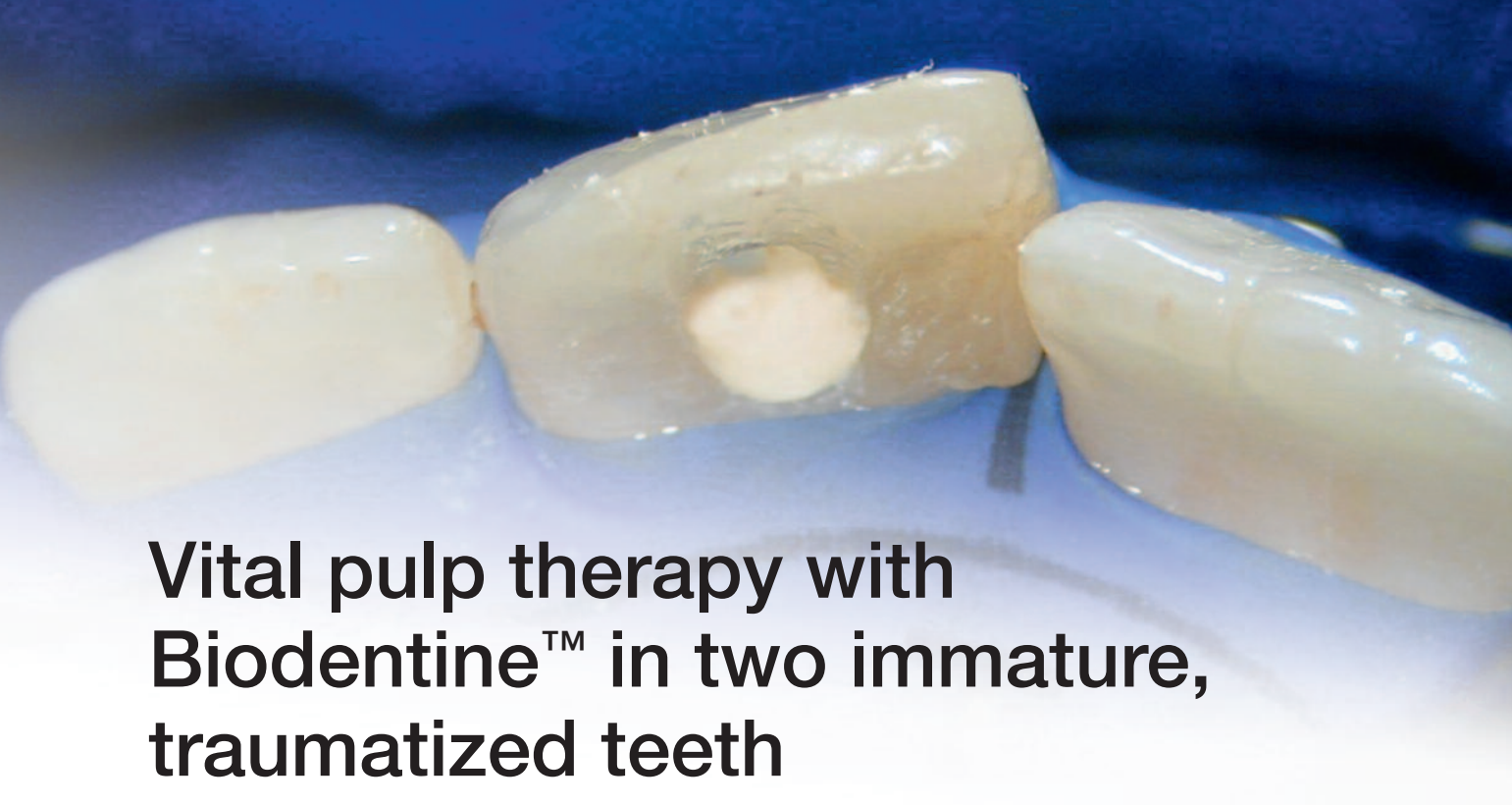01. Scarpelli AC, Reboucas AP, Compart T, Novaes-Júnior JB, Paiva SM, Pordeus IA. Seven-year follow-up of esthetic alternative for the restoration of peg-shaped incisors: a case study of identical twins. *Gen Dent.* 2008;56(1):74-7.
02. Peck S1, Peck L, Kataja M. Prevalence of tooth agenesis and peg-shaped maxillary lateral incisor associated with palatally displaced canine (PDC) anomaly. *Am J Orthod Dentofacial Orthop.* 1996;110(4):441-3.

Download the complete series

Septodont Case Studies Collection

www.septodont.com





Vital pulp therapy with Biodentine™ in two immature, traumatized teeth

Marga REE, DDS, MSc

Private Practice limited to Endodontics, Purmerend, Netherlands

Introduction

If pulp vitality in a young, permanent tooth is lost before root formation is completed, the clinician is confronted with a tooth that is more prone to fracture in case of a trauma, due to the presence of a root with very thin dentinal walls. In addition, the affected tooth might exhibit a poor crown-root ratio. Therefore, it is of utmost importance that pulp vitality should be preserved in an immature tooth with pulp involvement.

According to the definition of the AAE, the American Association of Endodontists, vital pulp therapy is a procedure to encourage apexogenesis. The requirements for a successful vital pulp therapy are remove a the presence of a non-inflamed or a reversibly-inflamed pulp, the ability the control the hemorrhage, the use of a biocompatible and bioactive pulp capping material and the creation of a bacteria-tight seal.

Over the course of time, several materials have been used as pulp capping agents. Calcium hydroxide has traditionally been the material of choice, followed by Mineral Trioxide Aggregate (MTA). MTA is described as a first generation bioactive material. It has many advantages, but also some disadvantages (1, 2). The initial setting

time is at least 3 hours. It is not easy to manipulate, resulting in considerable wasted material, and is hard to remove. Clinically, both gray and white MTA stain dentin, presumably due to the heavy metal content of the material or the inclusion of blood pigment while setting (3, 4). Efforts have been made to overcome these shortcomings with new compositions of MTA (5-7) or with additives (8, 9). However, these formulations affect MTA's physical and mechanical characteristics.

Bioceramics are inorganic, non-metallic, biocompatible materials that have similar mechanical properties as the hard tissues they are replacing or repairing. They are chemically stable, non-corrosive, and interact well with organic tissue. Bioceramic materials used in endodontics can be categorized by composition, setting mechanism and consistency. There are sealers and pastes, developed for use with gutta-percha, and putties, designed for use as the sole material, comparable to MTA. Biodentine™ is a calcium silicate cement that was developed as a dentine substitute in deep cavities. Comparable to MTA, Biodentine™ is biocompatible and in contact with vital tissues

it has been demonstrated to be bioactive and suitable to be used as a pulp capping agent (10, 11, 12). It has a higher compressive strength than MTA (12) and most glass ionomer cements, a higher flexural strength and flexural modulus than MTA Angelus (12) and can be applied in a bulk on dentin without any conditioning (13, 14). The material sets in 12 minutes and is capable to withstand deterioration when used as a temporary filling for up to 6 months (15).

In the opinion of the author, bioceramic materials have several advantages over MTA. In general, bioceramic materials have better clinical handling properties. The difficulties in handling of MTA have been frequently reported by clinicians (16).

Another drawback of MTA is the potential for staining dentin, which has been shown in several in vitro studies (4, 17, 18), clinical investigations (19, 20) and case reports (3, 21), which have shown that both white and gray MTA cause discoloration. To date, there have been no reports of staining of dentin by Biodentine™ or comparable bioceramic products, which has also been the experience of the author.

Several studies report that bismuth oxide, which acts as a radiopacifier in MTA (22, 23), may increase the cytotoxicity of MTA, because bismuth oxide does not encourage cell proliferation in cell culture (14). Biodentine™ contains zirconium oxide as opacifier.

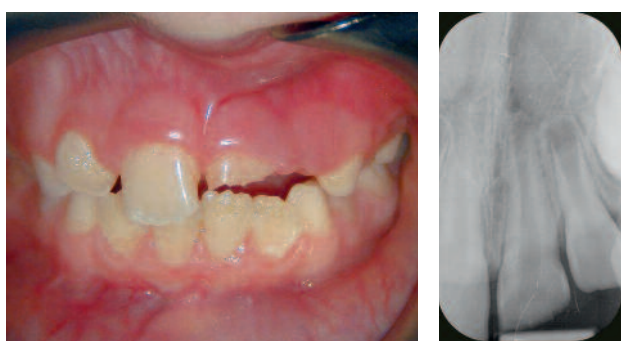


Fig. 1A: Clinical picture showing a complicated crown fracture in #21

Fig. 1B: Preoperative radiograph of #21 showing an immature tooth with an open apex and a complicated crown fracture

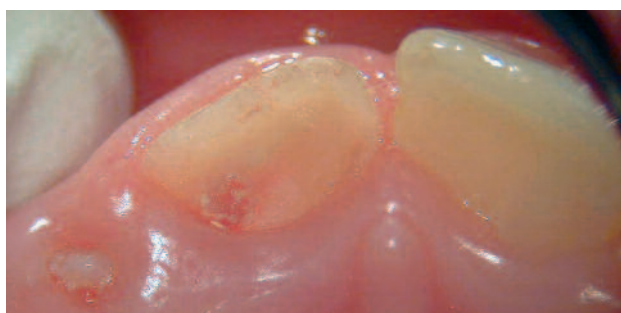

Fig. 1C: The palatal aspect of the fracture site, covered with plaque

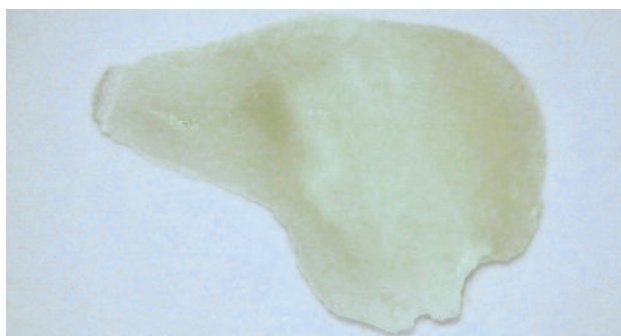


Fig. 1D: Photograph of the fragment, showing an oblique fracture line with the palatal outline below the gum line

Case Report

Patient #1 was a 7-year old female who suffered a traumatic dental injury to tooth #21 three days earlier. Her main complaints were sensitivity to warm and cold, and her medical history was noncontributory. Clinical examination revealed a crown fracture with pulp exposure of tooth #21 (Fig. 1A). Radiographically, #21 had an open apex and no peri-apical pathosis (Fig. 1B). The diagnosis was a complicated crown fracture with reversible pulpitis of tooth #21.

Treatment options were discussed with the patient and her parents, and a partial pulpotomy was selected as the treatment of choice. The fragment was stored by her parents, but due to the subgingival fracture site (Fig. 1C) and missing tooth structure in the fragment itself (Fig. 1D), it was not possible to re-attach the fragment to the tooth. Local anesthesia was administered (Septanest N, Septodont, Saint-Maur-des-Fossés, France) and a partial pulpotomy was carried out with a new diamond bur in a high speed hand-piece with copious water cooling. Since it was not possible to apply a rubber dam, utmost care was taken to keep a dry field and prevent saliva to contaminate the pulp tissue after the Cvek pulpotomy. A cotton pellet soaked in sodium hypochlorite 5% was applied on the

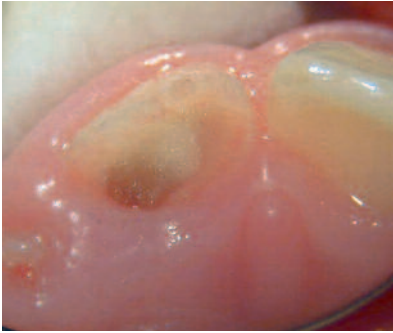


Fig. 1E: After a partial pulpotomy was carried out, a cotton pellet soaked in NaOCl 5% was applied to the pulp stump to stop the bleeding

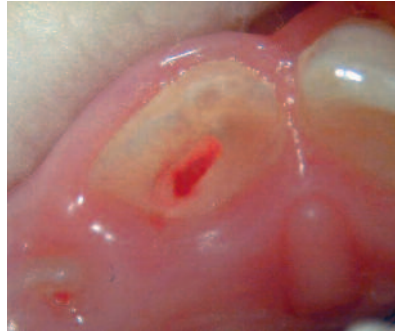

Fig. 1F: Clinical picture showing the hemorrhage was controlled

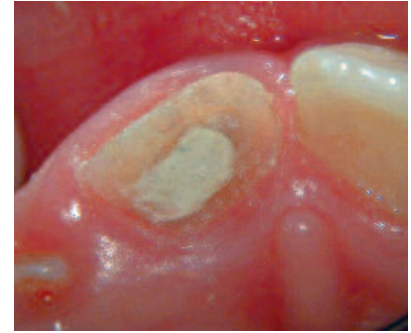

Fig. 1G: Biodentine™ was used as a pulp capping material

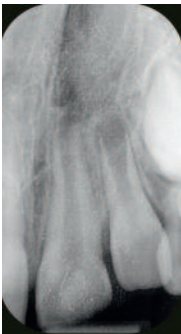

Fig. 1H: Postoperative radiograph of the pulp cap with Biodentine™, showing a material with moderate radiopacity

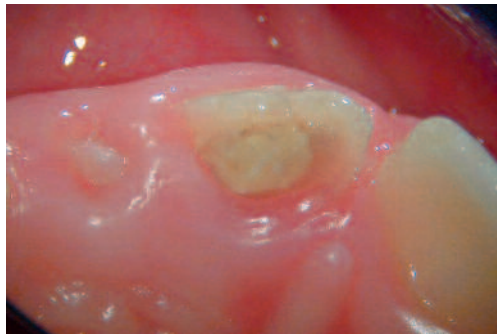

Fig. 1I: After one week, the Biodentine™ had not washed out

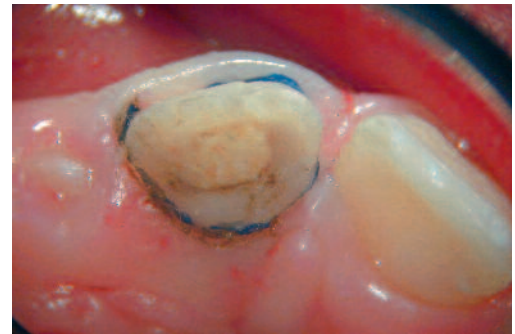

Fig. 1J: A retraction cord was packed into the sulcus to obtain a dry field and expose the subgingival margin of the palatal fracture site

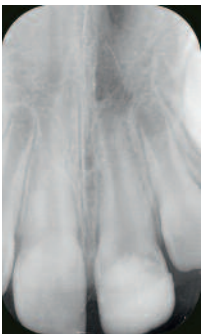

Fig. 1K: Postoperative radiograph showing the teeth restored with composite resin.

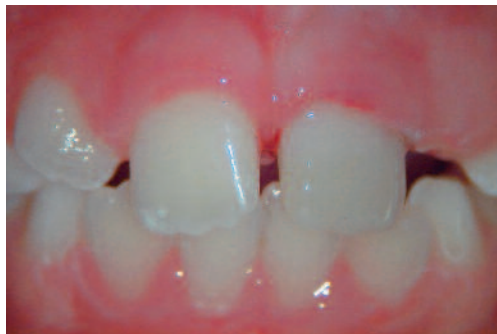

Fig. 1L: Clinical picture of the restoration of composite core material layered with a micro-filled composite at the buccal site

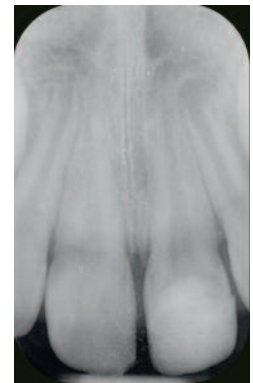
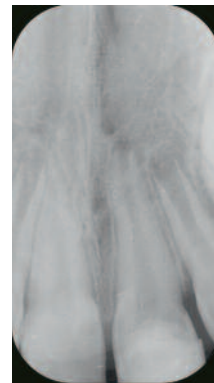
Fig. 1M/1N: Recall radiograph at 6 and 12 months, showing continued root formation

pulp stump with moderate pressure (Fig. 1E). After five minutes, the bleeding had stopped (Fig. 1F), and Biodentine™ (Septodont, Saint-Maur-des-Fossés, France) was applied as a pulp capping material to a thickness of approximately 3 mm with a Dovgan MTA carrier (Hartzell and Son, Concord, CA) (Fig. 1G-H). After the material had set in approximately 20 minutes, it was used as a temporary restoration. This is one of the advantages of the use of Biodentine™ over MTA, and makes it the material of choice in these type of cases. The patient was rescheduled for a second visit. After one week, the patient

returned and was asymptomatic. The Biodentine™ had fully set and had not washed out (Fig. 1I). A gingivectomy was carried out, and a retraction cord (Gingibraider, van R, Oxnard, CA, USA) was packed into the sulcus (Fig. 1J). Then a build-up of composite core material was placed (Luxacore; DMG, Hamburg, Germany), which was cut back on the buccal site and layered with a micro-filled composite (Filtek Supreme Ultra Universal Restorative, 3M ESPE, St. Paul, MN, USA) (Fig. 1K-L). Follow-up after 6 (Fig. 1M) and 12 months (Fig. 1N) showed a healthy tooth in full function with continuous root development.

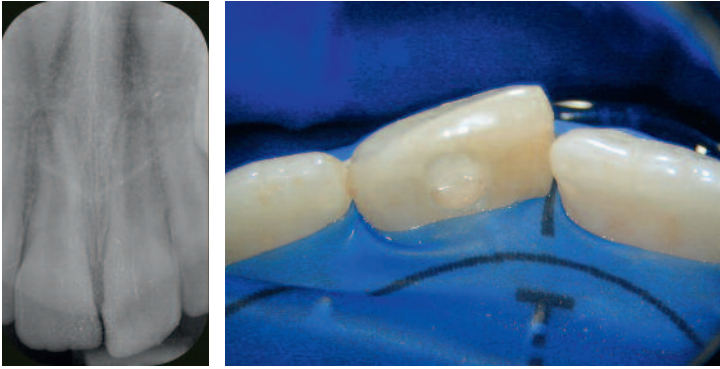


Fig. 2A: Preoperative radiograph of 21 showing a class IV restoration of composite resin and an immature root with an open apex
Fig. 2B: After a partial pulpotomy was carried out, a cotton pellet soaked in NaOCl 5% was applied to the pulp stump to stop the bleeding

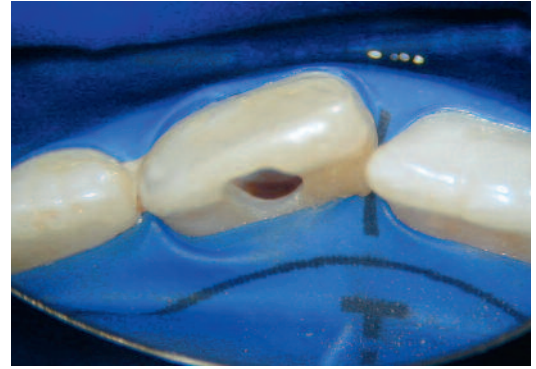

Fig. 2C: After a couple of minutes, the bleeding had stopped, which is indicative of healthy pulp tissue

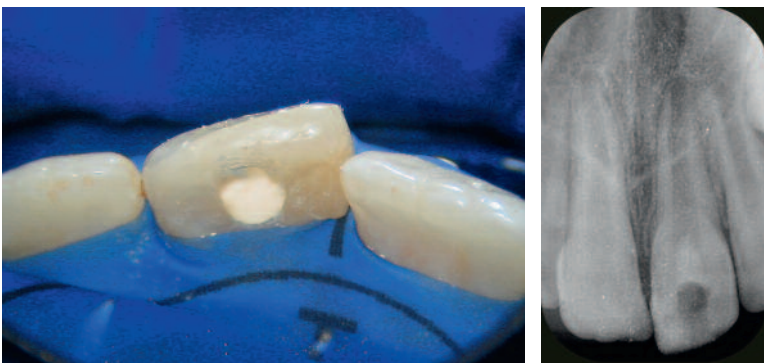


Fig. 2D/2E: Biodentine™ was used as a pulp capping material

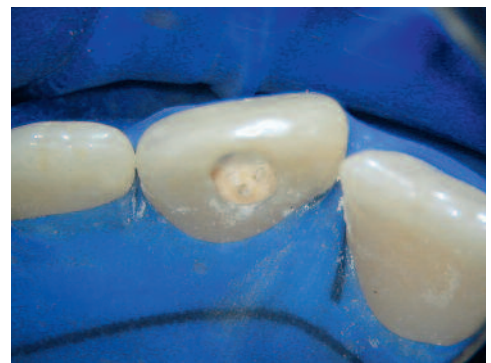

Fig. 2F: Photograph of the set Biodentine™

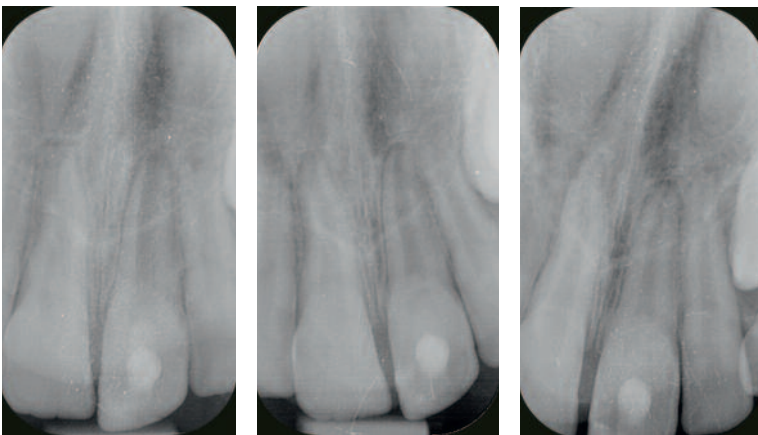


Fig. 2G: Postoperative radiograph showing the pulp-capped tooth restored with a composite resin
Fig. 2H/2I: At 6 and 18 months respectively, the patient was asymptomatic and the recall radiographs showed continued root development.

Patient #2 was an 8-year old male who was referred for advice and possible treatment of tooth #21. His medical history was noncontributory. Some months ago, he sustained an uncomplicated crown fracture of # 21. His dentist made a restoration of composite resin, that had to be replaced 5 times, because it came loose every single time. Since one week,

the patient had experienced severe sensitivity to hot and cold food and drinks. Clinical testing confirmed that tooth #21 was very sensitive to cold. A radiographic examination revealed that #21 had an open apex and no peri-apical pathosis (Fig. 2A). The diagnosis was an uncomplicated crown fracture with a reversible pulpitis in tooth #21.

Treatment options were discussed with the patient and his parents, and a partial pulpotomy was selected as the treatment of choice. Local anesthesia was administered (Septanest N, Septodont, Saint-Maur-des-Fossés, France), rubber dam was applied (Optradam, Ivoclar Vivadent, Schaan, Lichtenstein) and a partial pulpotomy was carried out with a new diamond bur in a high speed handpiece with copious water cooling. A cotton pellet soaked in sodium hypochlorite 5% was applied on the pulp stump with moderate pressure (Fig. 2B). After five minutes, the bleeding had stopped (Fig. 2C), and Biodentine™ (Septodont, Saint-Maur-des-Fossés, France) was applied as a pulp capping material to a thickness of several mm with a

Dovgan MTA carrier (Hartzell and Son, Concord, CA) (Fig. 2D-E). A moist cotton pellet was introduced on top of the Biodentine™, the access cavity was filled with a temporary filling, and the patient was rescheduled for a second appointment. After a week the patient returned asymptomatic. The Biodentine™ had fully set (Fig. 2F) and a build-up of composite core material was placed in the endodontic access cavity (Luxacore; DMG, Hamburg, Germany), with a top layer of a hybrid composite (Tetric Ceram, Ivoclar Vivadent, Schaan, Lichtenstein) (Fig. 2G). At the 6-month (Fig. 2H) and 18-month recall (Fig. 2I-J), the tooth was asymptomatic and showed apical maturation and continuous root development.

Conclusion

The author has presented 2 cases in which Biodentine™ was successfully used as a pulp capping material in an immature tooth with pulp involvement. In both cases, treatment

provided elimination of symptoms and continuation of root formation. In addition, no signs of discoloration were noticed after 6, 12 and 18 months respectively.



Author: Marga Ree

Marga Ree obtained her degree in dentistry from the University of Amsterdam in 1979. For the next five years she was a part-time staff member of the department of Cariology Endodontology Pedodontology, as well as being a clinical instructor in the central dental clinic of the University of Amsterdam. In 1998 she entered a postgraduate programme in endodontics, which she completed in 2001 with a Master of Science degree. Since that time she has lectured widely and taught hands-on courses throughout the Netherlands and abroad. She is the primary

author of several articles published in national and international journals and has contributed to several books on endodontics and restorative dentistry. Since 1980 she has had a private practice in Purmerend, which for the past fourteen years has been dedicated to endodontics.

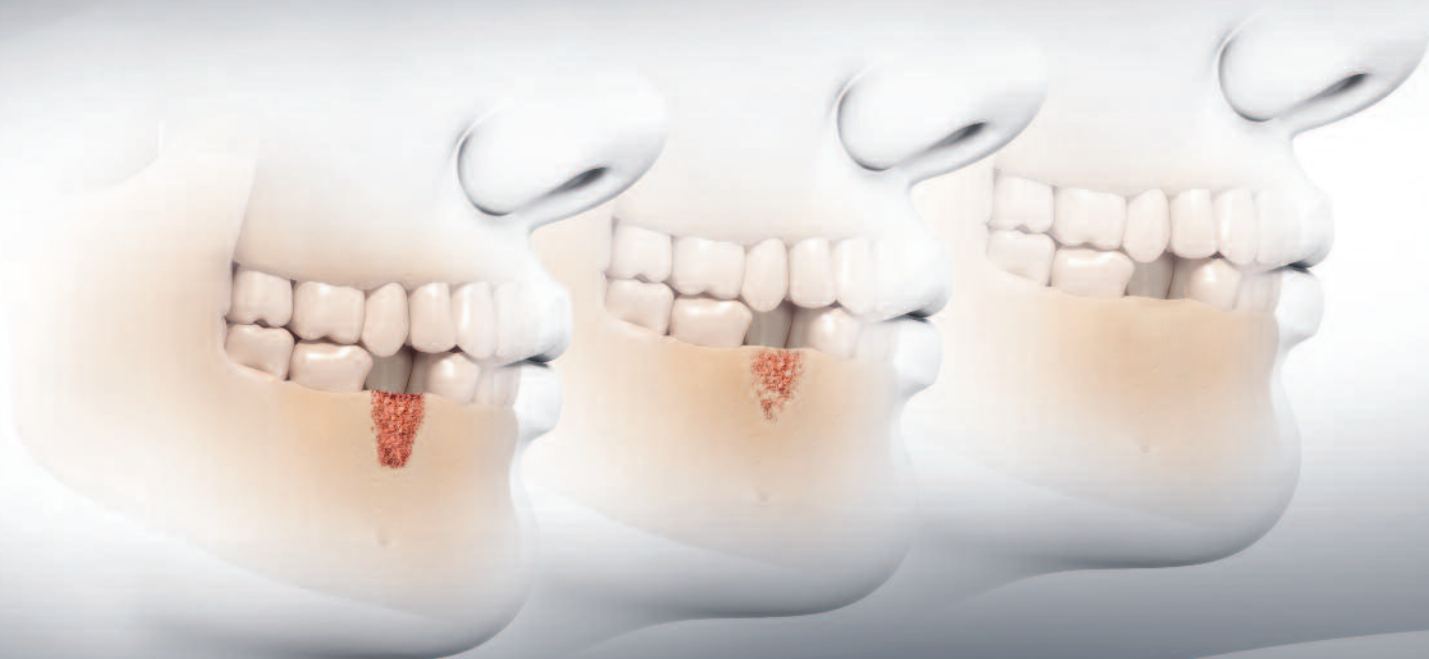References

01. Parirokh M, Torabinejad M. Mineral Trioxide Aggregate: a comprehensive literature review Part II – Leakage and biocompatibility investigations. *J Endod* 2010 Feb; 36 (2): 190-202.
02. Parirokh M, Torabinejad M. Mineral Trioxide Aggregate: a comprehensive literature review Part I – Chemical, physical and antibacterial properties. *J Endod* 2010 Jan; 36(1): 16-17.
03. Belobrov I, Parashos P. Treatment of tooth discoloration after the use of white mineral trioxide aggregate. *J Endod* 2011 Jul;37(7):1017-20.
04. Akbari M, Rouhani A, Samiee S, Jafarzadeh H. Effect of dentin bonding agent on the prevention of tooth discoloration produced by mineral trioxide aggregate. *Int J Dent*. 2012;2012:563203.
05. Antunes Bortoluzzi E, Juárez Broon N, Antonio Hungaro Duarte M, de Oliveira Demarchi AC, Monteiro Bramante C. The use of a setting accelerator and its effect on pH and calcium ion release of mineral trioxide aggregate and white Portland cement. *J Endod* 2006;32:1194-7.
06. Wiltbank KB, Schwartz SA, Schindler WG. Effect of selected accelerants on the physical properties of mineral trioxide aggregate and Portland cement. *J Endod* 2007;33: 1235-8.
07. Ber BS, Hatton JF, Stewart GP. Chemical modification of ProRoot MTA to improve handling characteristics and decrease setting time. *J Endod* 2007;33:1231-4.
08. Kogan P, He J, Glickman GN, Watanabe I. The effects of various additives on setting properties of MTA. *J Endod* 2006;32:569-72.
09. Jafarnia B, Jiang J, He J, Wang YH, Safavi KE, Zhu Q. Evaluation of cytotoxicity of MTA employing various additives. *Oral Surg Oral Med Oral Pathol Oral Radiol Endod*. 2009;107:73944.
10. Shayegan A, Jurysta C, Atash R, Petein M, Abbeele AV. Biodentine used as a pulp-capping agent in primary pig teeth. *Pediatr Dent*. 2012 Nov-Dec;34(7):e202-8.
11. Nowicka A, Lipski M, Parafiniuk M, Sporniak-Tutak K, Lichota D, Kosierkiewicz A, Kaczmarek W, Buczkowska-Radlińska J. Response of human dental pulp capped with biodentine and mineral trioxide aggregate. *J Endod*. 2013 Jun;39(6):743-7.
12. Natale LC, Rodrigues MC, Xavier TA, Simões A, de Souza DN, Braga RR. Ion release and mechanical properties of calcium silicate and calcium hydroxide materials used for pulp capping. *Int Endod J*. 2014 Mar 20.
13. Laurent P, Camps J, De Méo M, Déjou J, About I. Induction of specific cell responses to a Ca(3)SiO(5)-based posterior restorative material. *Dent Mater*. 2008 Nov;24(11):1486-94
14. Raskin A, Eschrich G, Dejou J, About I. In vitro microleakage of Biodentine as a dentin substitute compared to Fuji II LC in cervical lining restorations. *J Adhes Dent*. 2012 Dec;14(6):535-42.
15. Koubi G, Colon P, Franquin JC, Hartmann A, Richard G, Faure MO, Lambert G. Clinical evaluation of the performance and safety of a new dentine substitute, Biodentine, in the restoration of posterior teeth - a prospective study. *Clin Oral Investig*. 2013 Jan;17(1):243-9.
16. Parirokh M, Torabinejad M. Mineral Trioxide Aggregate: a comprehensive literature review Part III – Clinical applications, drawbacks and mechanisms of action. *J Endod* 2010 Mar; 36 (3): 400-13.
17. Boutsoukis C, Noula G, Lambrianidis T. Ex vivo study of the efficiency of two techniques for the removal of mineral trioxide aggregate used as a root canal filling material. *J Endod* 2008 Oct;34(10):1239-42.
18. Jang JH, Kang M, Ahn S, Kim S, Kim W, Kim Y, Kim E. Tooth discoloration after the use of new pozzolan cement (Endocem) and mineral trioxide aggregate and the effects of internal bleaching. *J Endod* 2013 Dec;39(12):1598-602.
19. Maroto M, Barbería E, Vera V, García-Godoy F. Dentin bridge formation after white mineral trioxide aggregate (white MTA) pulpotomies in primary molars. *Am J Dent*. 2006;19:75-79.
20. Percinoto C, de Castro AM, Pinto LM. Clinical and radiographic evaluation of pulpotomies employing calcium hydroxide and trioxide mineral aggregate. *Gen Dent*. 2006;54:258-261.
21. Jacobovitz M, de Lima RK. Treatment of inflammatory internal root resorption with mineral trioxide aggregate: a case report. *Int Endod J*. 2008 Oct;41(10):905-12.
22. Camilleri J, Montesin FE, Brady K, Sweeney R, Curtis RV, Ford TR. The constitution of mineral trioxide aggregate. *Dent Mater*. 2005 Apr;21(4):297-303.
23. Park JW, Hong SH, Kim JH, Lee SJ, Shin SJ. X-Ray diffraction analysis of white ProRoot MTA and Diadent BioAggregate. *Oral Surg Oral Med Oral Pathol Oral Radiol Endod*. 2010 Jan;109(1):155-8.
24. Camilleri J, Montesin FE, Papaioannou S, McDonald F, Pitt Ford TR. Biocompatibility of two commercial forms of mineral trioxide aggregate. *Int Endod J*. 2004 Oct;37(10):699-704.

R.T.R.

Full resorption...

...Strong new bone formation



Cone



Syringe



Granules

R.T.R. (Resorbable Tissue Replacement) is a highly pure β -tricalcium phosphate bone grafting material that helps to safely create new bone formation following an extraction or any bone loss (intra-bony defect, sinus-lift...).

- **Resorbs progressively and fully:** R.T.R. releases calcium and phosphate ions helping to promote strong new bone formation.
- **Regenerates natural bone growth.** Osteoconductive micro and macroporous structures foster dense new bone growth.
- **Restores volume:** R.T.R. renews the bone integrity within 3-6 months.
- **Available in 3 presentations** (Cone, Syringe, Granules) to suit all clinical situations.

Improve your patients' extraction therapy and bone loss repair to promote future implant success with R.T.R.

R.T.R. Cone contains collagen from bovine origin





The Dental Pharmaceutical Company

INNOVATIVE, SAFE AND EFFECTIVE SOLUTIONS FOR DENTISTRY WORLDWIDE