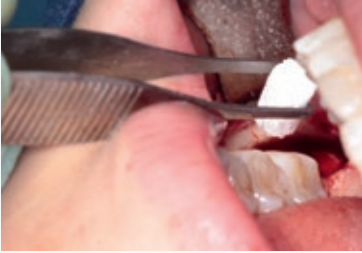

# Septodont Case Studies *Collection*

No. 17 - September 2018

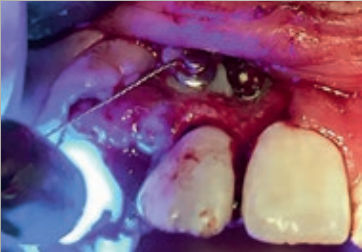
## Alveolar preservation with R.T.R

Dr Gabriela Vilar Pineda



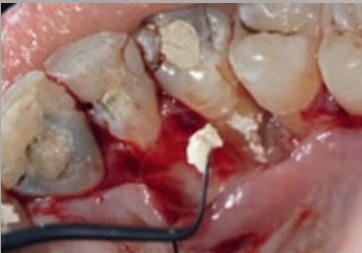## Biodentine™: external resorption management

Dr Maximiliano Casa



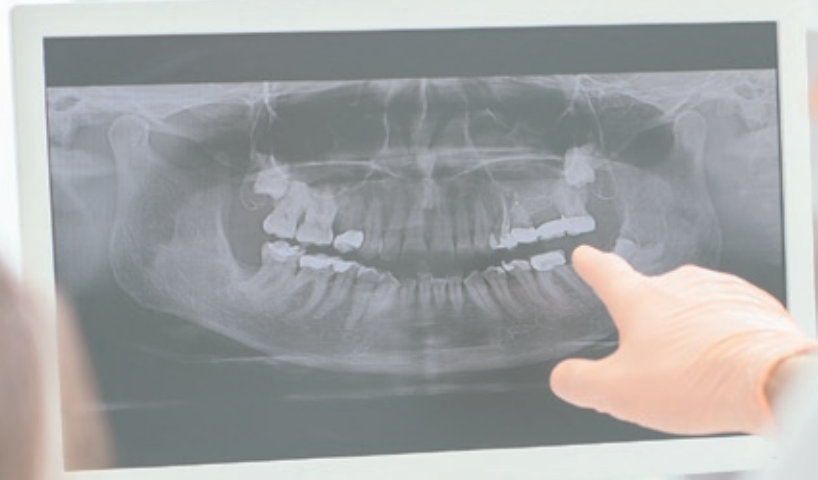
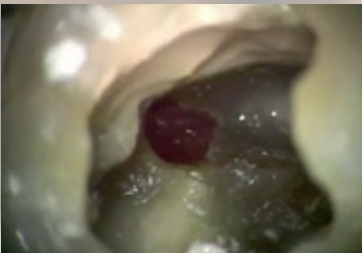## Biodentine™: root reconstruction

Prof. Fernando Tenorio



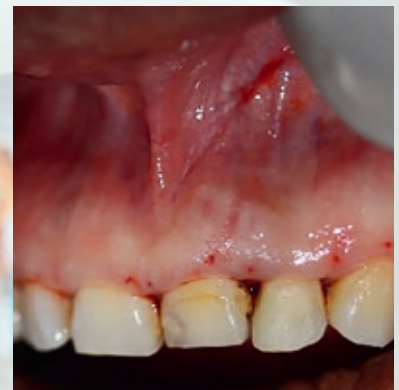## Biodentine™: perforation repair

Dr Alberto Diaz Tueme

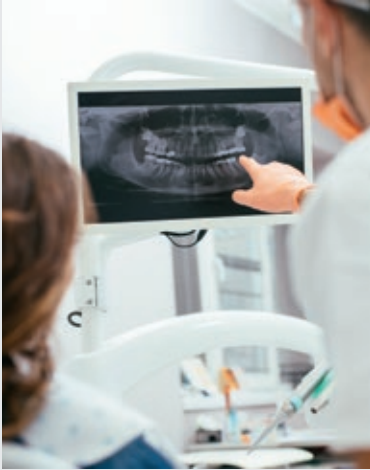

## Biodentine™: retrograde apical microsurgery

Dr Carlos Herrera



# Editorial



Since its foundation Septodont has developed, manufactured and distributed a wide range of high quality products for dental professionals.

Septodont recently innovated in the field of endodontics, dentine care, bone grafting and gingival preparation with the introduction of BioRoot™ RCS, Biodentine™, RTR and Racegel which are appreciated by clinicians around the globe.

Septodont created the “Septodont Case Studies Collection” - a series of case reports - in 2012 to share with you their experience and the benefits of using these innovations in daily practice.

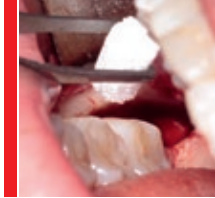Over the past 6 years, authors from more than 15 countries have generously contributed to the success of our magazine that is now distributed on the 5 continents.

Each new issue of the Case Studies Collection is the opportunity to discover new clinical challenges and their treatment solutions.

This 17<sup>th</sup> issue features one RTR case and three Biodentine™ cases:

- RTR Bone grafting aims at preserving bone dimensions especially when tooth removal is discussed. It is fully resorbable & osteoconductive. Its remarkable properties promote formation of patient's new bone & pave the way for future successful treatment plans.
- Biodentine™, the first biocompatible and bioactive dentin replacement material. Biodentine™ uniqueness not only lies in its innovative bioactive and “pulp-protective” chemistry, but also in its universal application, both in the crown and in the root.

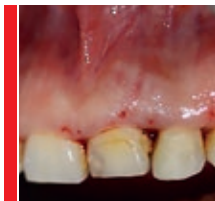# Content



## **Alveolar preservation with R.T.R**

Dr Gabriela Vilar Pineda

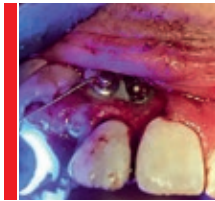04



## **Biodentine™: retrograde apical microsurgery**

Dr Carlos Herrera

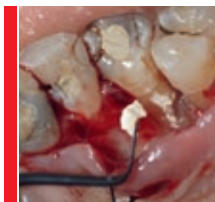13



## **Biodentine™: external resorption management**

Dr Maximiliano Casa

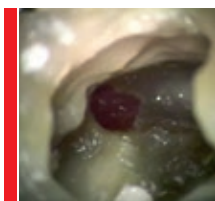
21



## **Biodentine™: root reconstruction**

Prof. Fernando Tenorio

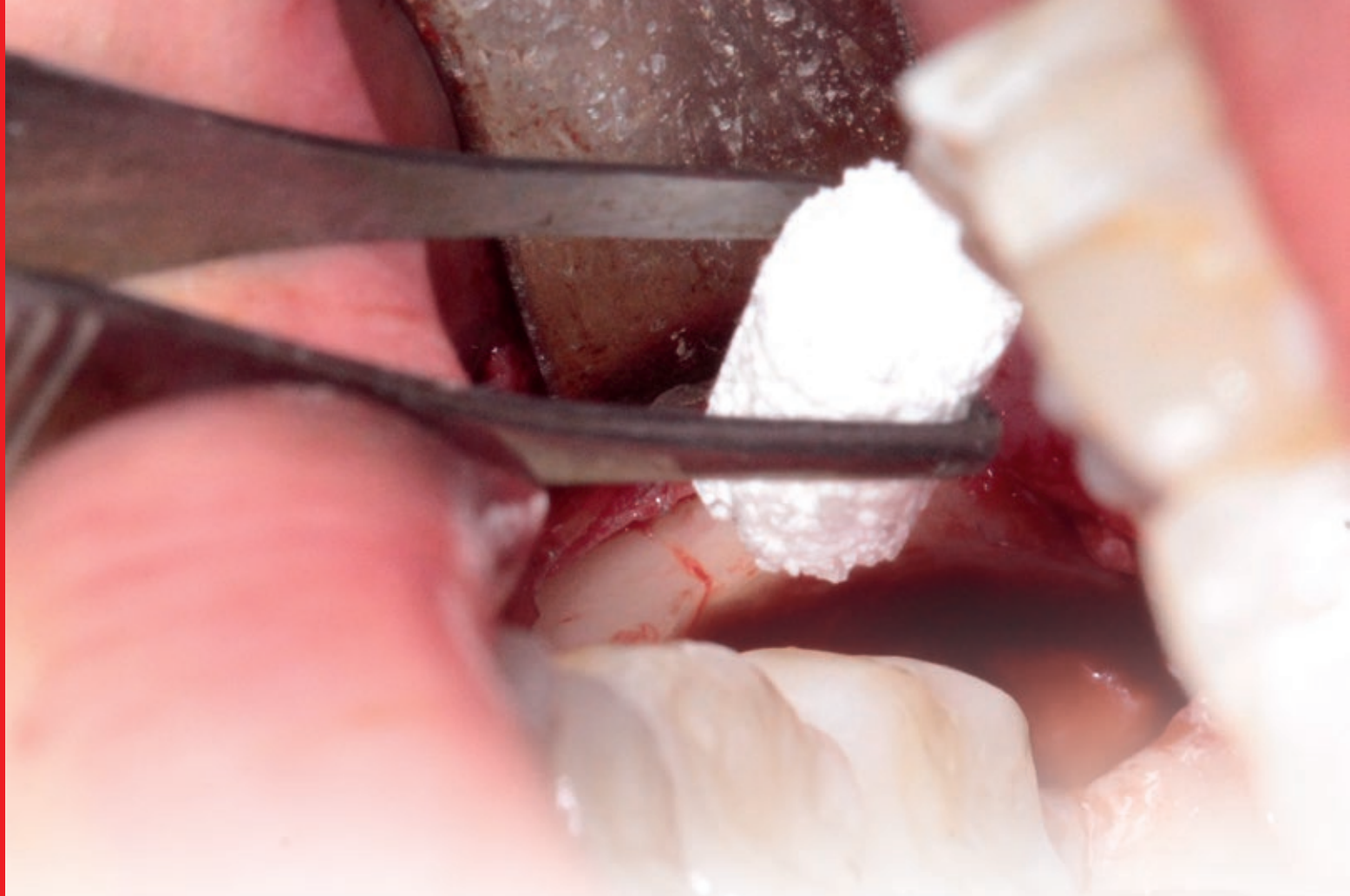29



## **Biodentine™: perforation repair**

Dr Alberto Diaz Tueme

34



# Use of $\beta$ -tricalcium phosphate for alveolar preservation; a report on a series of cases.

Authors: Medina Ramírez Jorge Michel\*, Gabriela Vilar Pineda\*\*, René García Contreras\*\*\*.  
Corresponding author: Gabriela Vilar Pineda.

## Summary

$\beta$ -tricalcium phosphate is a high purity material that helps to safely generate bone neoformation after tissue extraction or loss. Preservation treatment was performed using a  $\beta$ -tricalcium phosphate cone (R.T.R Cone, Septodont, France) in the lower right quadrant, at the lower third molar area (tooth 48), for research purposes; it was kept under observation for periods of 1 week, 1 month and 3 months. In

the quadrant with the R.T.R, favorable bone neoformation process was observed in a shorter time compared to the left quadrant, and a progressive and total reabsorption of the R.T.R was observed after 3 months. The use of  $\beta$ -tricalcium phosphate is a useful alternative for post-extraction alveolar preservation, improving the speed of bone regeneration.

\*Student of Dentistry at the National School of Higher Studies of the National Autonomous University of Mexico, León Unit (ENES UNAM León Unit).

\*\*Specialist in Oral and Maxillofacial Surgery at the ENES of the UNAM, León Unit.

\*\*\*Doctor of Health Sciences at ENES/UNAM, León Unit.

# Introduction

Bone regeneration with alveolar preservation following tooth extraction has been a topic of major significance recently due to the use of dental implants as a method of esthetic and functional rehabilitation;<sup>(1)</sup> the improvement of regeneration time is therefore a significant issue, and for such purpose alveolar preservation techniques using various materials have been proposed (hard and soft tissue grafts) in view of maximizing tissue preservation and minimizing defects.<sup>(2)</sup>

$\beta$ -tricalcium phosphate ( $\beta$ -TCP) is a synthetic ceramic bone graft material that has been in use in medicine and dentistry for more than 30 years, in the fields of orthopedics, periodontology and maxillofacial surgery. Pore size varies from 5 to 500  $\mu\text{m}$ , and the porosity ranges from 20 to 90% depending on particle size. For dental use, particle size is generally less than 100  $\mu\text{m}$ .<sup>(3)</sup> Used as a graft material,  $\beta$ -TCP stands in for the mechanism of osteoconduction; when it is used in the

biological process, the material is reabsorbed and replaced by the recipient's own bone. The interconnection between pores facilitates osteoconduction. When the graft is placed at the receptor site, some serum proteins are absorbed and retained on the surface of the particles, contributing to the subsequent cellular migration that will stimulate a neovascularization process in the porous structure.<sup>(3)</sup> The R.T.R. (Resorbable Tissue Replacement), is composed of  $\beta$ -tricalcium phosphate, a material used for alveolar preservation after a tooth removal when posterior prosthetic rehabilitation is planned. The objective of the following series of clinical cases was to evaluate the alveolar preservation achieved with the use of R.T.R. cones and without the use of R.T.R. by radiographic evaluations at three-month follow-up. Case reporting was conducted in compliance with Case Report Guidelines (CARE).

# Report on a series of cases

Four patients were selected to conduct alveolar preservation with the use of  $\beta$ -tricalcium phosphate (R.T.R) cones; these patients were required to meet certain criteria. The inclusion criteria used for this report were: patients of both sexes, retained third molars Pell & Gregory class I and II subdivision A and B, bilateral, age range between 18 and 22 years, no periodontal or periapical disease in the lower molar region, and willingness to perform the alveolar preservation procedure for research purposes. The exclusion criteria used for this report were: patients with uncontrolled systemic diseases, acute infectious processes, pregnant or lactating patients, patients with bone diseases, use of bisphosphonates, and poor oral hygiene.

Patients meeting the admission criteria for the clinics and oral surgery department of the "Escuela Nacional de Estudios Superiores", of the UNAM, León Unit, were evaluated.

Auxiliary diagnostic studies were performed (Panoramic radiographs, Periapical views), and no disorders being found in any patient, a diagnosis was made in the full series of cases; retained third molars Pell & Gregory class I and II, subdivision A and B, bilateral.

The patients signed informed consent forms in which they are made aware of the diagnosis, treatment plan and possible complications during treatment.

## PATIENT 1

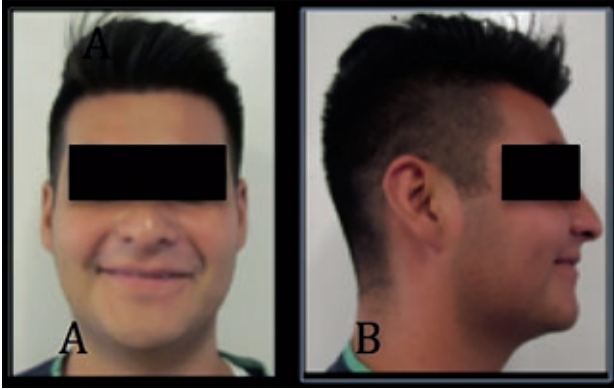

Fig. 1: Extraoral photographs  
(A: frontal B: lateral)

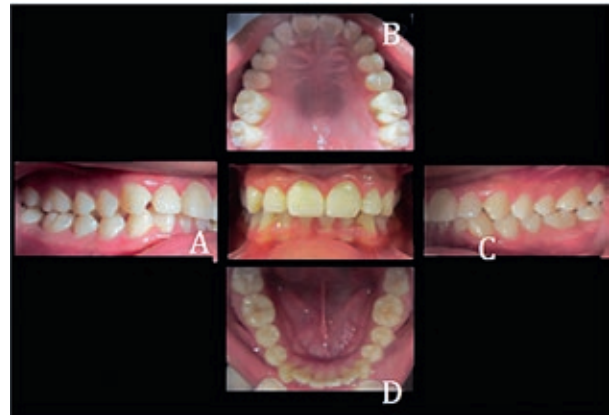

Fig. 2: Intraoral photographs  
(A: right side B: top C: left side D: bottom)

## PATIENT 2

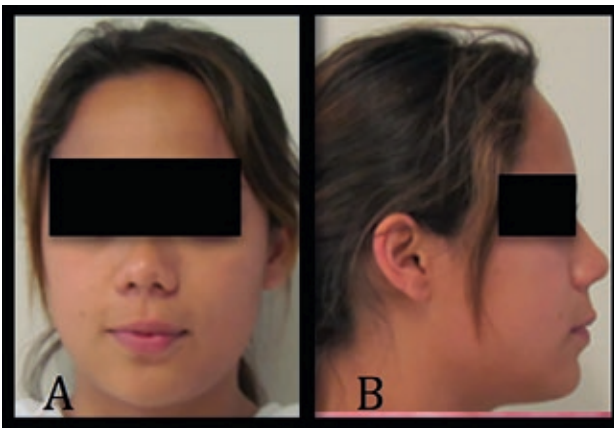


Fig. 3: Extraoral photographs  
(A: frontal B: lateral)

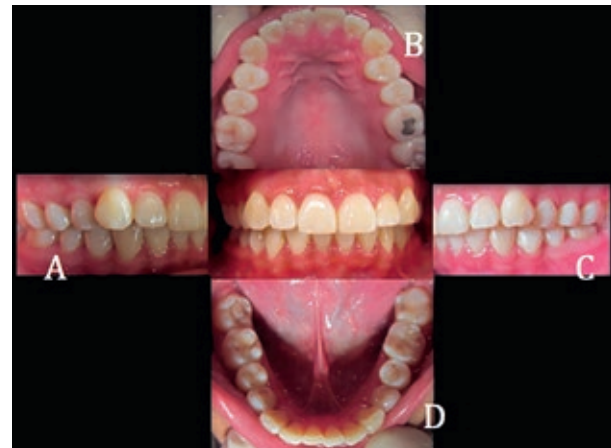

Fig. 4: Intraoral photographs  
(A: right side B: top C: left side D: bottom)

## PATIENT 3

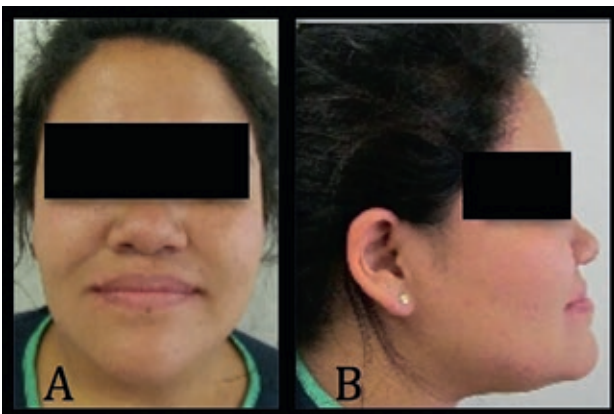


Fig. 5: Extraoral photographs  
(A: frontal B: lateral)

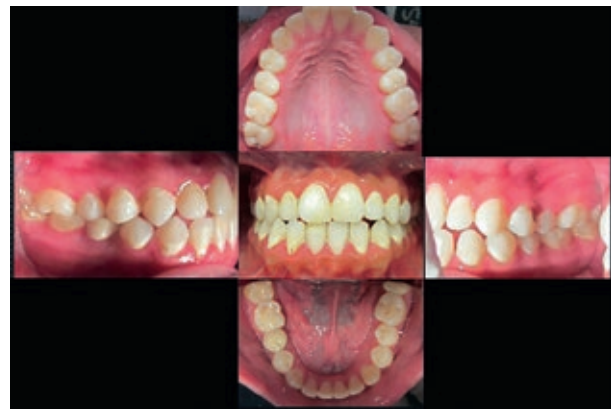
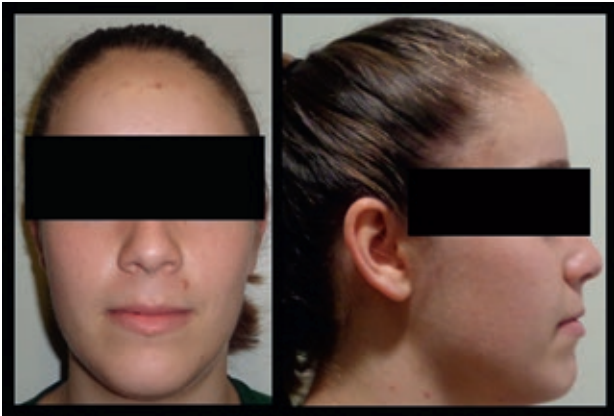
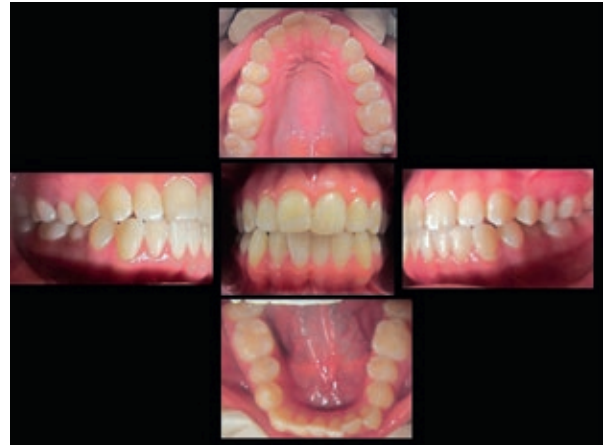Fig. 6: Intraoral photographs  
(A: right side B: top C: left side D: bottom)

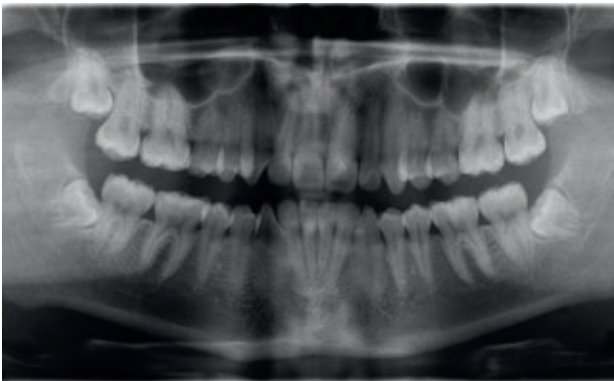
## PATIENT 4



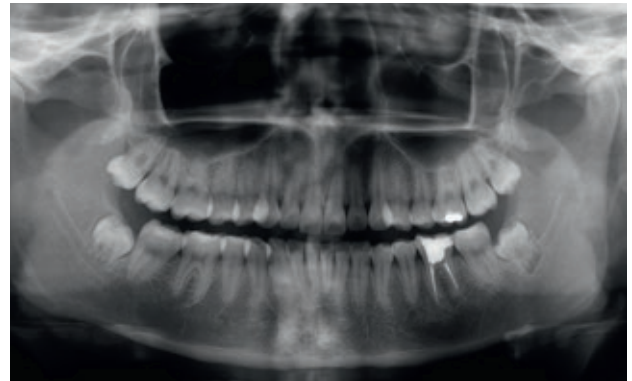
*Fig. 7:* Extraoral photographs  
(A: frontal B: lateral)



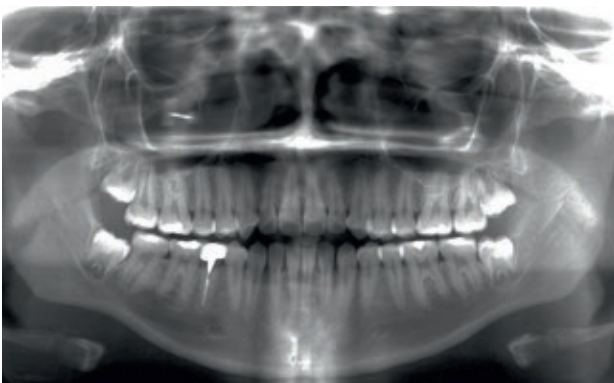
*Fig. 8:* Intraoral photographs  
(A: right side B: top C: left side D: bottom)



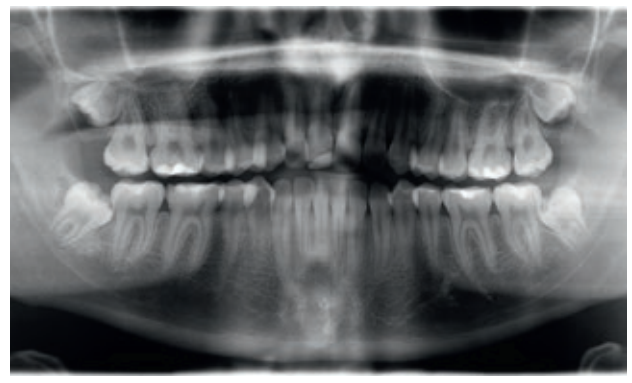
*Fig. 9:* Initial panoramic radiograph, patient 1.



*Fig. 10:* Initial panoramic radiograph, patient 2.



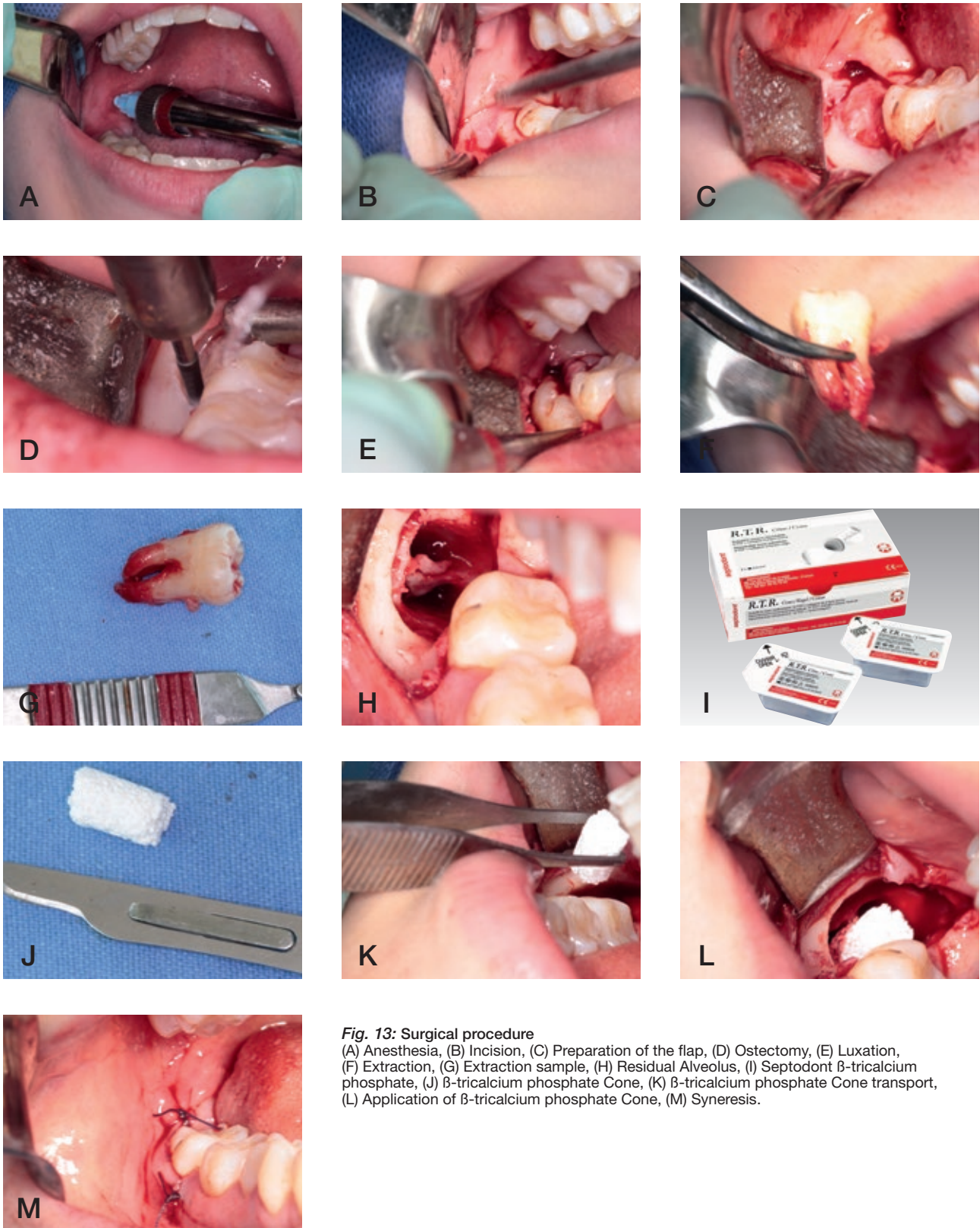
*Fig. 11:* Initial panoramic radiograph, patient 3.



*Fig. 12:* Initial panoramic radiograph, patient 4.

Surgical odontectomies of teeth 38 and 48 were performed under local anesthesia by infiltration with lidocaine and epinephrin 2%, 1:100,000; a Newman's incision was performed, the mucoperiosteal flap lifted, osteotomy and odontectomy conducted, the cavity washed, and a cone of  $\beta$ -tricalcium phosphate (R.T.R) placed in the residual alveolus of tooth 48; on the

opposite side the lower left quadrant in the area of tooth 38 was left with nothing placed inside the alveolus, and both sides were sutured using polyglactin 910 4/0; postoperative management with Amoxicillin 500 mg, 1 every 8 hours for 5 days, and Ibuprofen 400 mg, 1 every 8 hours for 3 days; instructions for general postoperative measures were likewise provided.



**Fig. 13: Surgical procedure**  
 (A) Anesthesia, (B) Incision, (C) Preparation of the flap, (D) Osteotomy, (E) Luxation, (F) Extraction, (G) Extraction sample, (H) Residual Alveolus, (I) Septodont  $\beta$ -tricalcium phosphate, (J)  $\beta$ -tricalcium phosphate Cone, (K)  $\beta$ -tricalcium phosphate Cone transport, (L) Application of  $\beta$ -tricalcium phosphate Cone, (M) Syneresis.

Patients were evaluated 7 days after surgery; good evolution was observed, with an adequate healing process underway; radiographically, a mixed image was observed (black and white radiographic image), interpreted as the  $\beta$ -tricalcium phosphate cone (R.T.R) in tooth 48, and

a radiolucent image was observed in tooth 38, corresponding to the residual alveolus; after a month of evolution, we were able to observe improved healing. The area treated with R.T.R showed larger areas of radiopacity, interpreted as improved bone neoformation compared to the



residual alveolar process area at tooth 38, where slower bone formation was observed, considering the greater areas of radiolucency. The third month of observation allowed us to verify the presence of improved bone regeneration,

a radiopaque image of the residual alveolus at tooth 48, in addition to total reabsorption of the material, as indicated by the manufacturer, and reduced bone trabeculation compared to the residual alveolar process area at tooth 38.

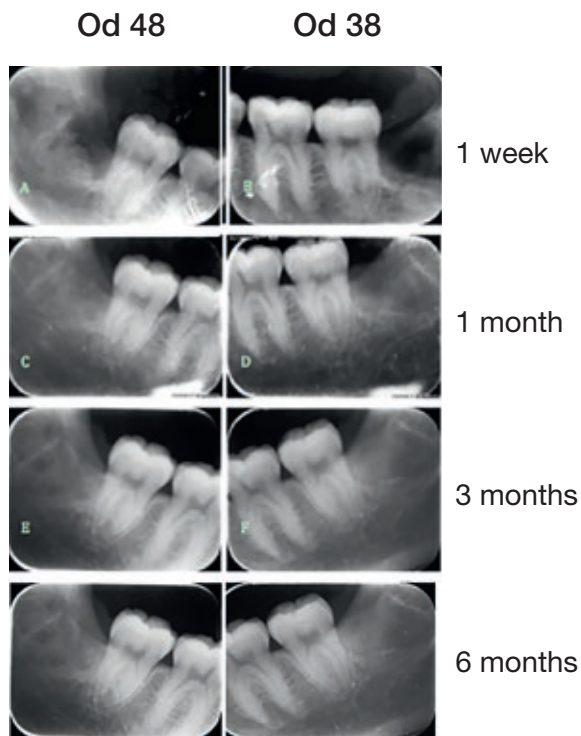


Fig. 14: Control periapical radiograph patient 1

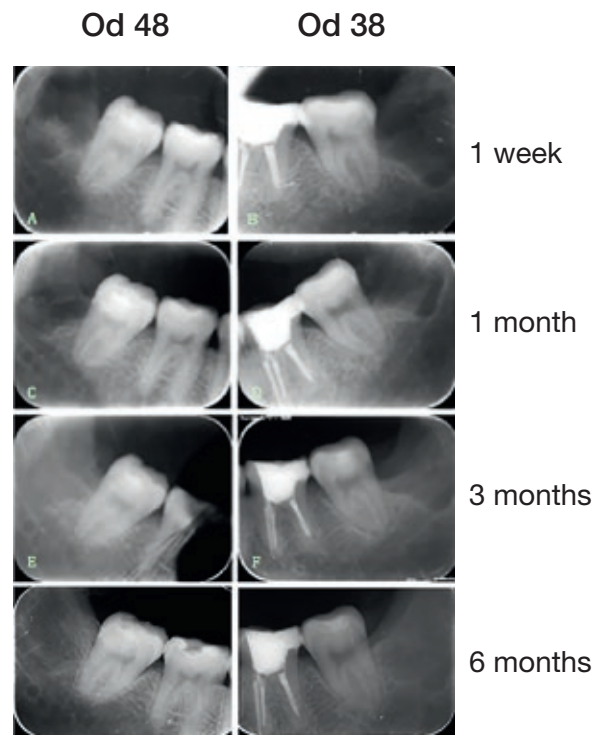


Fig. 15: Control periapical radiograph patient 2

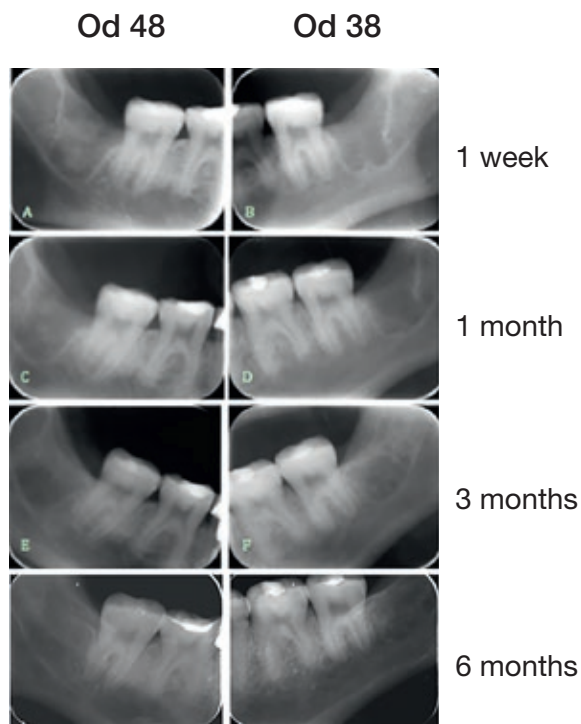


Fig. 16: Control periapical radiograph patient 3

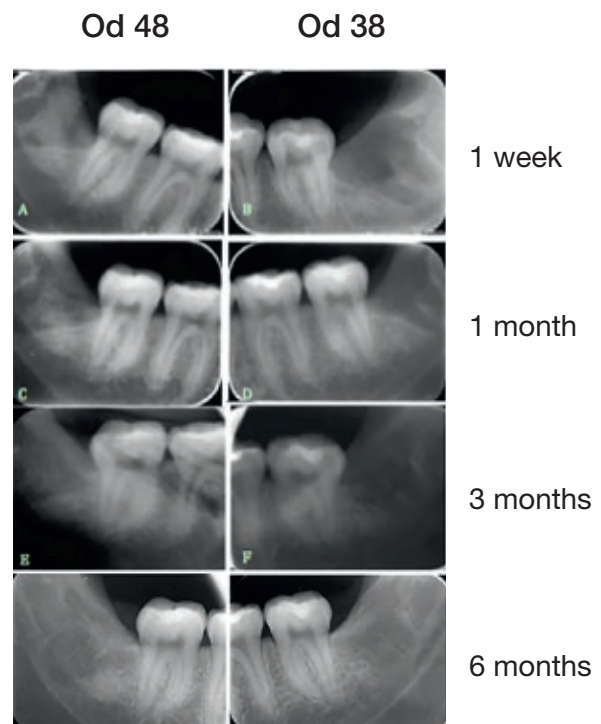


Fig. 17: Control periapical radiograph patient 4

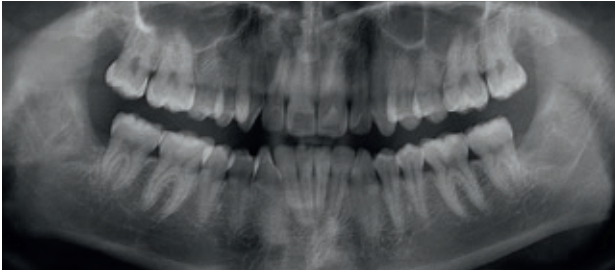


Fig. 18: Panoramic radiograph, 3 months, patient 1.

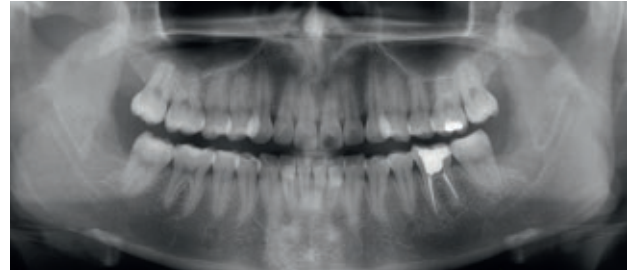


Fig. 19: Panoramic radiograph, 3 months, patient 2.

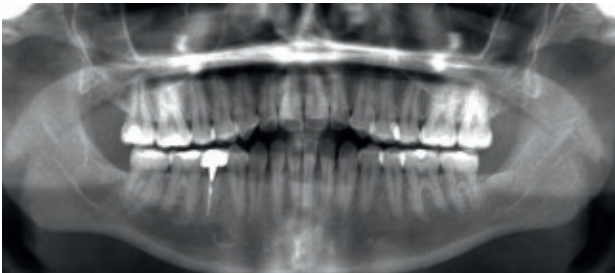


Fig. 20: Panoramic radiograph, 3 months, patient 3.

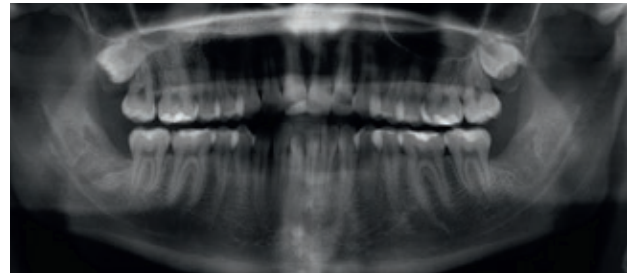


Fig. 21: Panoramic radiograph, 3 months, patient 4.

## Discussion

Classically, the ideal material considered for bone regeneration has been autologous bone. However, in recent decades new materials of human, animal or synthetic origin have been incorporated into the arsenal, which have revolutionized alveolar preservation techniques.<sup>(4)</sup> The action of  $\beta$ -tricalcium phosphate (R.T.R) on alveolar preservation, in comparison to the natural bone healing process, has been proven.<sup>(5)</sup> As for its regeneration mechanism,  $\beta$ -tricalcium phosphate (R.T.R) is a biocompatible material that would seem to have scaffold action permitting osteoblasts to grow on its surface and invade its structure.<sup>(3)</sup> It has proved to be an excellent biomaterial with high success in bringing about the bone regeneration necessary to maintain adequate space for implant insertion.<sup>(6)</sup>

When the  $\beta$ -tricalcium phosphate is reabsorbed, it is replaced by bone that is anatomically and functionally similar to the original bone, thus producing regenerated vital bone tissue, which means that this bone remodeling and maturation process, necessary for the functional loading of implants, is not disturbed by the material.<sup>(7)</sup> Residual elements may occasionally remain, which can be demonstrated clinically and radiologically after 6 months.<sup>(8)</sup>

The overall results of the study showed that at clinical follow-up, 1 year after the functional loading of implants (6 months after surgery), no failures were observed in either the implants or the various different implant-supported prosthodontic options.<sup>(9)</sup>

## Conclusion

In light of the case reports discussed above it was thus observed that after 3 months of observation the time of bone neoformation was significantly improved where R.T.R was used,

as compared to the residual alveolar process where no alloplastic material had been placed; R.T.R is thus a choice material for the effective post-odontectomy preservation of alveolar bone.

## Author:



### **Dra. Gabriela Vilar Pineda**

Dental Surgeon specialized in Oral and Maxillofacial Surgery by the Faculty of Dentistry of the National Autonomous University of Mexico (UNAM) and recertified by the Mexican Council of Oral and Maxillofacial Surgery.

Master of Education with focus on Innovation in Teaching Practice. She currently works as a Career Researcher and Holder of the Degree in Dentistry of the National School of Advanced Studies (ENES) at the UNAM Campus León. She actively

participates as an academic in several Continuing Education Programs, recently recognized for her performance in the field of Oral and Maxillofacial Surgery with the distinction of participation in the Scientific Commission of the Mexican Association of Oral and Maxillofacial Surgery.

She held the position of Associate Professor of the subject of Pharmacology in the Division of Postgraduate Studies and Research by the UNAM from August 2010 to July 2011.

Coordinator of the University Diploma "Professional Update in Oral Surgery for the Dentist of General Practice" in the period of August 2008 to July 2011.

Coordinator of the Diploma "Training and Update for Dental Assistants" in the period of February 2010 to July 2011, both taught through the Continuing Education Coordination of the Faculty of Dentistry of the UNAM.

At the bachelor's level teaches the theoretical-practical subjects of Anatomy-Physiology of the Segment, Head and Neck, Problem-Based Learning, Introduction to Surgical Procedures, Exodontia and Human Anatomy Physiology.

In addition, teaches the subject of Cardiopulmonary Resuscitation; within other subjects that have been taught are Exodontia, Oral Surgery, Dental Medical Emergencies and Anesthesia in the period of July 2005 to July 2011 at the Faculty of Dentistry of the UNAM.

She was Professor of Pharmacology, Toxicology and Clinical Analysis at the Faculty of Biological Sciences of the Westhill University in the period of August 2008 to December 2009.

She also was Professor of Exodontia and Surgery Oral at the Faculty of Dentistry of the Autonomous University of the State of Mexico (UAEM) in the period of September 2005 to March 2006.

Among the activities that he has carried out throughout his academic practice are the following: Synodal of professional exams at bachelor's degree, Tutor and Adviser of thesis to undergraduate students of the Faculty of Dentistry at the UNAM.

Tutor of undergraduate students in the programs "BECALOS", "PARA" and "PRONABES", all of these by the Faculty of Dentistry of the UNAM and of the National School of Advanced Studies of the UNAM Campus León.

In her professional experience she has worked as a Physician assigned to the Oral and Maxillofacial Surgery Service at the Social Security Institute of the State of Mexico and Municipalities (ISSEMYM) from July 2005 to July 2011, simultaneously as a Physician attached to the Oral and Maxillofacial Surgery Service of the Teachers' Union at the service of the State of Mexico in the period of January 2009 to July 2011.

She has also worked in a private practice in the "Hospital Angeles Mexico" in the period of October 2004 to April 2012 and currently a private practice in the "Hospital Angeles León".

She has publications in national and international journals with topics with Craniomandibular Dysfunction and Regenerative Medicine, including some studies on Health, Education and Happiness.

She has participated as a national and international lecturer in conferences, courses and congresses in the area of Maxillofacial Surgery, with topics such as Orthognathic Surgery, Dentoalveolar Surgery, Implantology, Craniomandibular Dysfunction, Tissue Regeneration and Regenerative Medicine among others.

Currently, she is responsible for projects PAPIIME (Project Support Program for Innovation and Improvement of Teaching), Multi-centric and International Research Projects and joint projects with the area of Biomedical Engineering of the Autonomous University of Aguascalientes and develops research projects in the area of Craniomandibular Dysfunction and Regenerative Medicine.

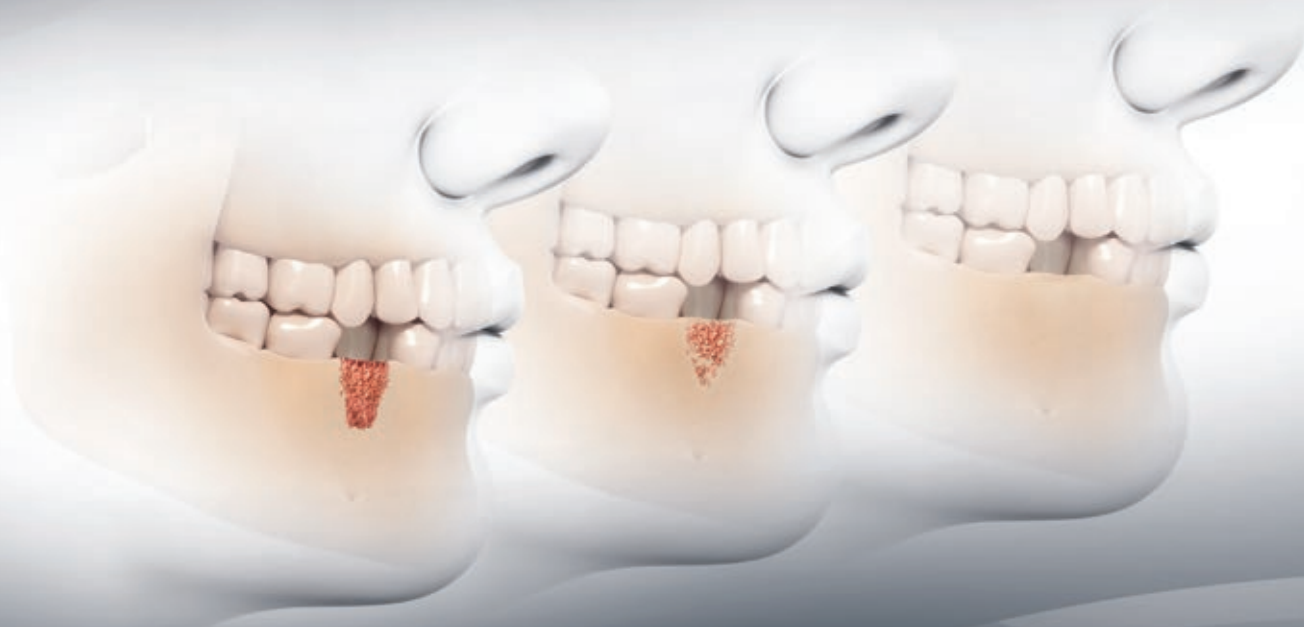## References

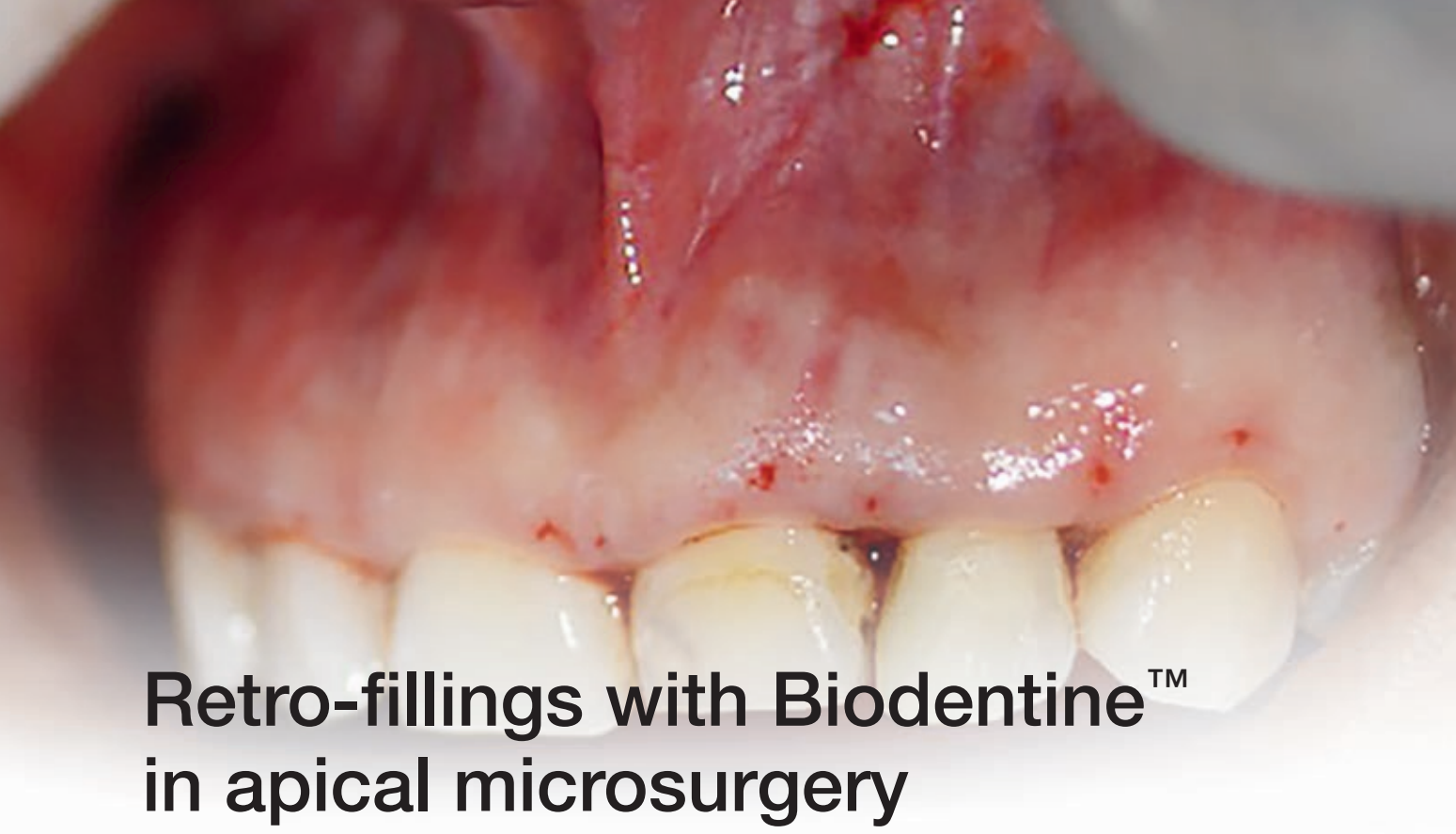---

1. Araujo MG, Lindhe J. Dimensional ridge alterations following tooth extraction. An experimental study in the dog. *J Clin Periodontol.* 2005;32:212-8.
2. De, P., Ernesto, M., & Briseño, G. (2015). Materiales de injerto substitutos óseos. Fosfato tricálcico  $\beta$ . Presentación de casos clínicos. [Bone substitute graft materials.  $\beta$ -tricalcium phosphate. Presentation of clinical cases.]
3. Labanca M, Leonida A, Rodella, Natural synthetic biomaterial in Dentistry: Science and ethics as criteria for their use. *Implantologia.* 2008; 1: 9-23
4. Jensen SS, Broggin N, Horting-hansen E, Schenk R, Buser D. Bone healing and graft resorption of autograft, anorganic bovine bone and beta-tricalcium phosphate. A histologic and histomorphometric study in the mandibles of minipigs. *Clin Oral Impl Res* 2006; 17: 237-43.
5. Salgado Castellanos, J., Zea del Rio, D. M., Gonzalez Miranda, J. M., & Velosa Porras, J. (2014). Effectiveness of Alveolar Preservation Techniques over Post-Extraction Socket Compared with and without Socket Preservation. Systematic Review of Literature. *Universitas Odontologica*, 33(70). <https://doi.org/10.11144/Javeriana.UO33-70.etpa>.
6. Jensen OT, Garlini G, Bilk D, Peters F. Use of alloplasts for sinus floor grafting. In: Jensen OT. *The sinus bone graft* (2nd ed.). Quintessence: Chicago 2006. pg.: 201-9.
7. Trisi P, Rao W, Rebaudi A, Fiore P. Histologic effect of pure-phase beta-tricalcium phosphate on bone regeneration in human artificial jaw bone defects. *Int J Perio Rest Dent* 2003; 23: 69-77.
8. Suba Z, Takács D, Matusovits D, Barabás J, Fazekas A, Szabó G. Maxillary sinus floor grafting with  $\beta$ -tricalcium phosphate in humans: density and microarchitecture of the newly formed bone. *Clin Oral Impl Res* 2006; 17: 102-108.
9. Zijdeveld SA, Zerbo IR, van der Bergh JPA, Schulten EAJM, ten Bruggenkate CM. Maxillary sinus floor augmentation using a  $\beta$ -tricalcium phosphate (Cerasorb) alone compared to autogenous bone grafts. *Int J Oral Maxillofac Implants* 2008; 20: 432-40.

# R.T.R.

A complete solution  
for your bone needs





# Retro-fillings with Biodentine™ in apical microsurgery

Dr Carlos Herrera

## Introduction

The technique of microsurgery is a minimally invasive procedure that results in faster healing and better patient response. The key stage of microsurgery is inspection, which is entirely absent from older surgical techniques. Untreated isthmuses often mean that treatment fails, so they must be identified, cleaned, shaped and filled as carefully as root canals (Floratos and Kim 2017).

Osteotomy in microsurgery is becoming more and more conservative thanks to the improved magnification and lighting offered by microscopes. The diameter of osteotomy is only 3 to 4 mm, enough to allow a 3 mm ultrasound tip to vibrate freely inside the bone cavity (Kim, Pecora and Rubinstein 2001).

Careful examination will identify the possible reason or reasons for the failure of non-surgical treatment, the magnification and lighting provided by the surgical microscope being critical. (Kim, Pecora and Rubinstein 2001; Cohen and Burns 1994 and 2002; Lubow, Wayman and Cooley 1984).

Various retro-filling materials have been used in recent years, such as: amalgam, gold foil, zinc oxide eugenol cement, Diaket (ESPE GmbH, Seefeld, Germany), glass ionomer cements, composite resins, intermediate restorative material (Putty / Dentsply, Milford, DE, USA), Super EBA (Bosworth, Skokie, IL, USA) and mineral trioxide aggregate (MTA; ProRoot MTA; Dentsply, Tulsa, OK, USA). Although none of these meet every criterion for an ideal repair material, MTA has been the preferred choice for root-end fillings (Torabinejad and Pitt 1996).

In the present cases, we used Biodentine™ from among the new biosilicate materials as a retro-filling material, developed by Septodont Research Group as a new class of dental material which could combine excellent mechanical properties, biocompatibility and clinical use, with a formula based on calcium silicate ( $\text{Ca}_3\text{SiO}_5$ ), a tried and tested replacement material where the dentin is damaged. (Biodentine™ Septodont 2010)

The following cases of microsurgery were retro-filled with Biodentine™ by Septodont.

# Clinical case study no.1

Female patient, 43 years of age, referred to assess apical microsurgery treatment in 2.1 and 2.2 central and left upper incisors. The patient displayed symptoms in both teeth; sensitivity tests revealed pain on tapping and palpation, with radiolucent lesion in both teeth, previously treated pulp diagnoses and symptomatic periapical apical periodontitis, the radiographic examination revealed extruded gutta-percha

in the periapical region of 2.1. The patient reported that she had previously received two retreatments but the pain continued in both teeth; retreatment was carried out to remove the gutta-percha on tooth 2.1, which was not possible, obturation with biodentine™ with subsequent removal of the gutta-percha and apicoectomy; on tooth 2.2 microsurgery was carried out with retro-filling with biodentine™.

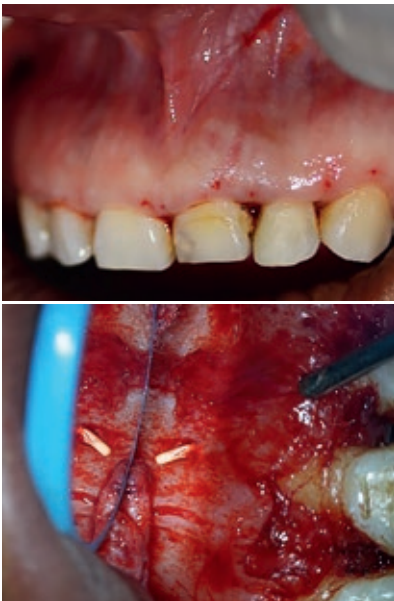


Fig. 1 & 2: Initial photographs of 2.1 and 2.2.

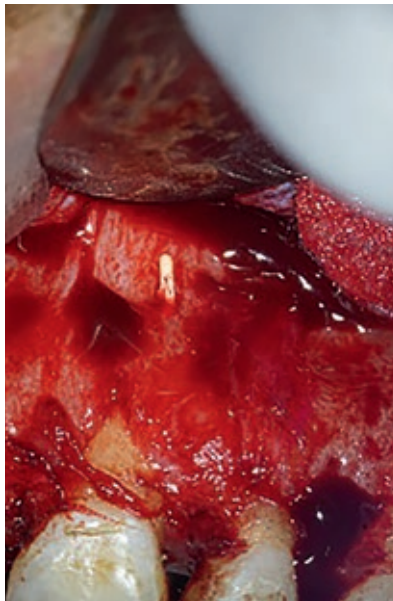


Fig. 3: Extruded gutta-percha in the periapical region of 2.1

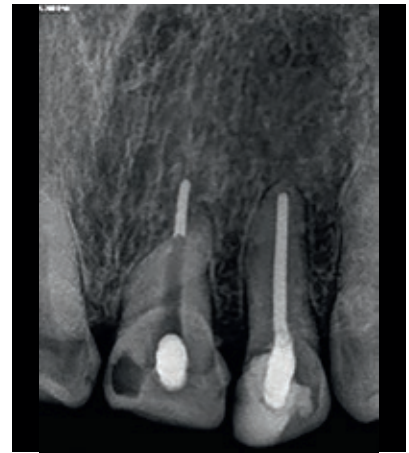

Fig. 4: Initial radiography 06-24-16

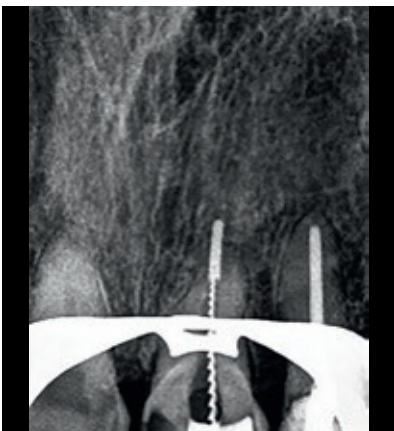

Fig. 5: attempt to remove the gutta-percha 2.1

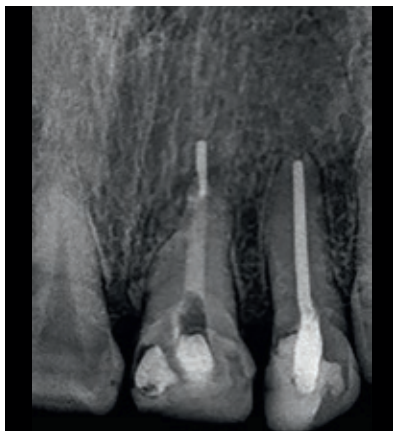

Fig. 6: retreatment of tooth 2.1

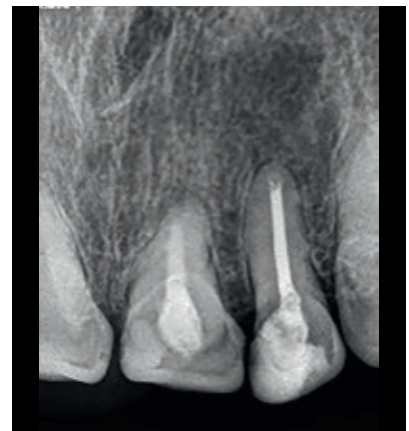
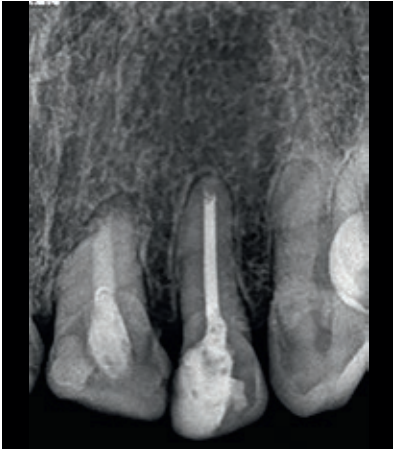
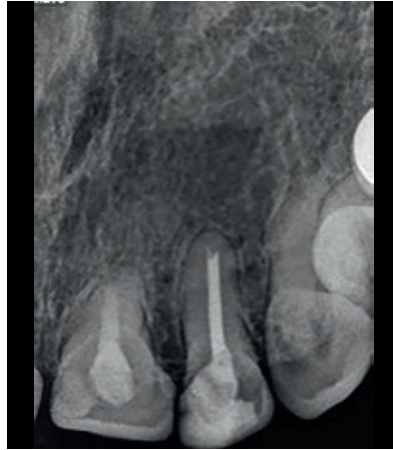Fig. 7: Apical microsurgery control Apicoectomy of 2.1 And retro-filling of 2.2 with Biodentine™.

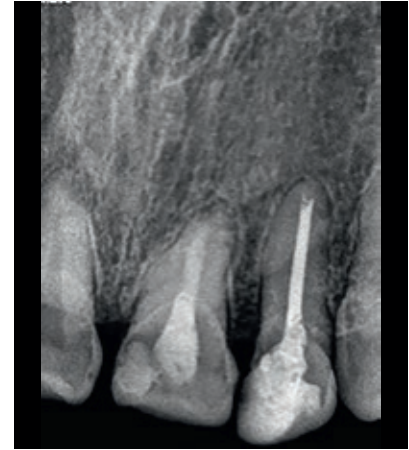Apicoectomy of tooth 2.1 and retro-filling with biodentine™ of tooth 2.2



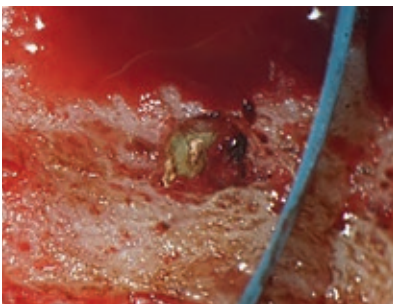
**Fig. 8:** First control 11-25-16 after 5 months



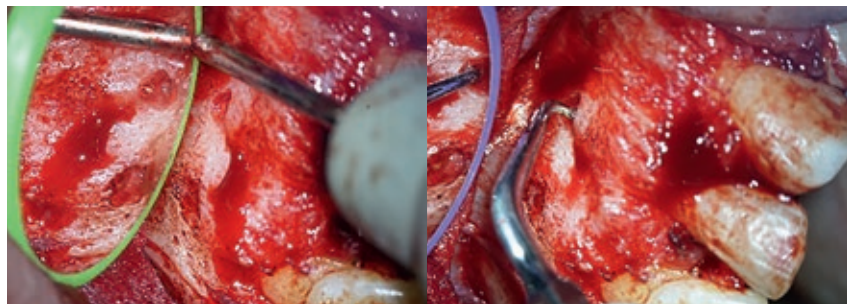
**Fig. 9:** Second control 02-25-17 after 8 months



**Fig. 10:** Third control 06-29-17 after 1 year

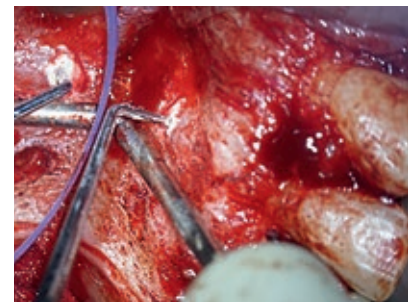


**Fig. 11:** First control 11-25-16 after 5 months



**Fig. 12 & 13:** Retrograde cavity of 2.2

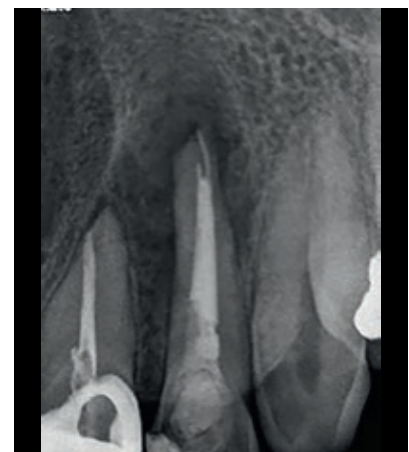The patient currently presents no symptoms with no clinical or radiographic findings at the 1-year follow-up, and shows evidence of healthy and functional teeth.



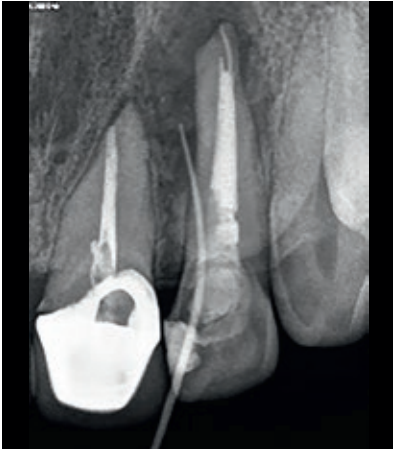
**Fig. 14:** Condensation of retrofilling with Biodentine™ in 2.2

## Clinical case study no.2

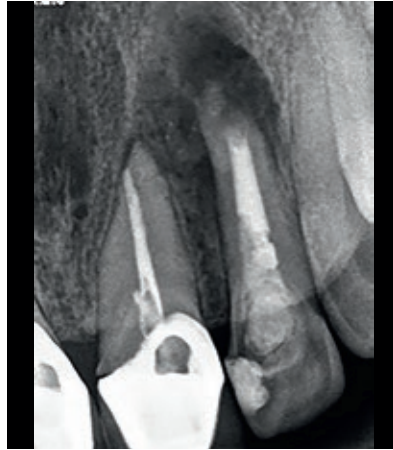Male patient, 44 years of age; referred to assess Apical Microsurgery of 2.2 upper left lateral incisor. Clinical and radiographic findings: fistula at the mucosa of the tooth, evolution of the wound: approximately 5 years; history of two retreatments in that time; the patient reported having no symptoms; radiograph revealed failure of endodontic treatment with placement of a fiber glass post, light area in the periapical zone; Pulp Diagnosis: previously treated; Periapical Diagnosis: chronic Apical Abscess.



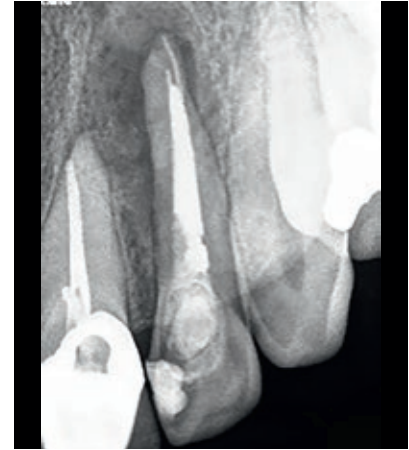**Fig. 15:** Initial Rx Microsurgery 11-07-2013



*Fig. 16:* Initial Rx 11-07-2013.



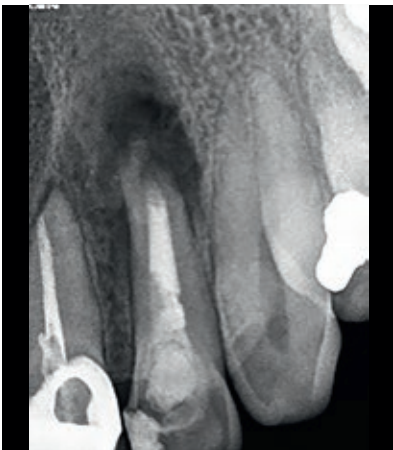*Fig. 17:* Sinugraphy 11-07-2013.



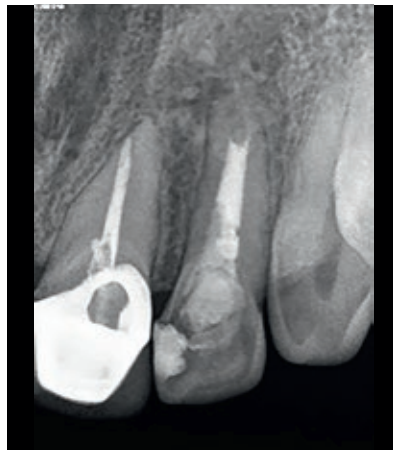*Fig. 18:* End of Retro-filling with Biodentine™.

Apical microsurgery was performed with retro-filling with biodentine™ of 2.2; apicoectomy with removal of 3 millimeters of the apical root canal; irrigation with saline solution, curettage

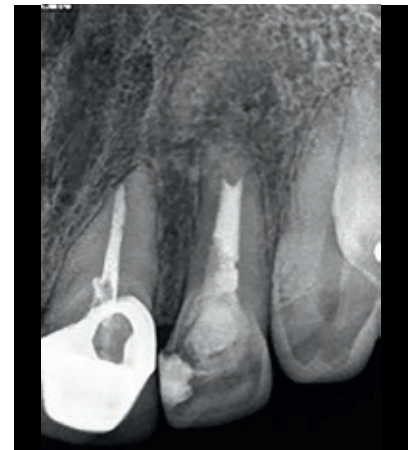and removal of the damage confirming a periapical cyst through biopsy and histopathological examination.



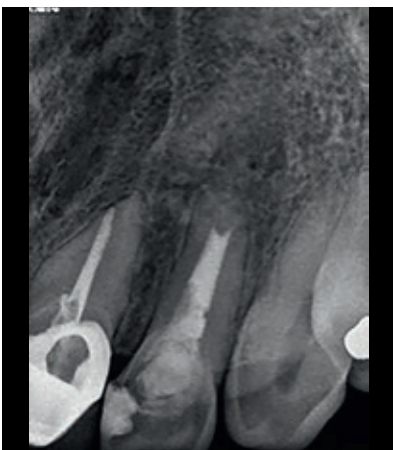*Fig. 19:* First control at one month after treatment 12-15-2013.



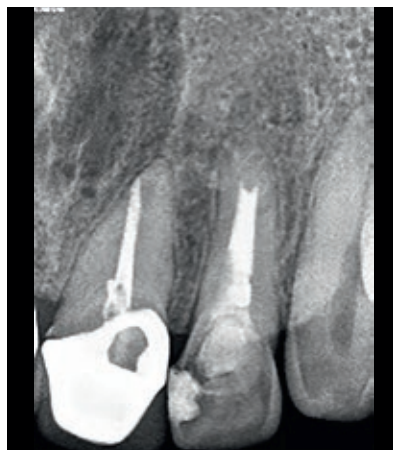*Fig. 20:* Second control at 2 years and 5 months 04-07-2016.



*Fig. 21:* Third control at 3 years and 1 month 12-12-2016.



*Fig. 22:* Fourth control at 3 years and 4 months 04-11-2017.



*Fig. 23:* Fifth control at 3 years and 10 months 10-10-2017.

At the control at 3 years and 10 months we can observe full regeneration of the wound, patient totally asymptomatic at the date of control both clinically and with evidence of healing in the radiographic examination.



# Clinical case study no.3

Male patient, 72 years of age, referred to assess 1.1 right upper central incisor; in his dental history the patient had received root canal treatment and final restoration 4 years earlier. Clinical and radiographic findings: metal and porcelain crown, fiber glass post, periapical

radiolucent lesion of considerable size; sensitivity tests were performed; the patient was asymptomatic with mild discomfort when biting, positive response to tapping and palpation, previously treated pulp diagnosis and asymptomatic periapical Apical Periodontitis.

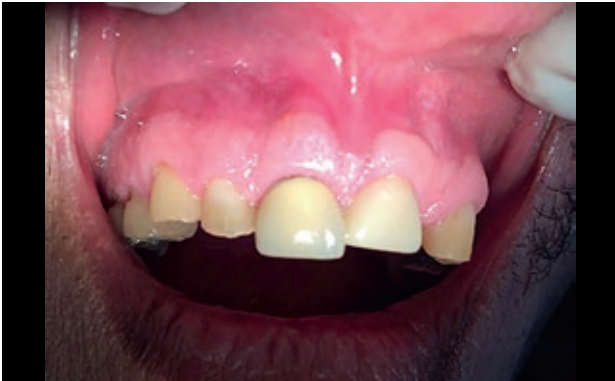

Fig. 24: Initial photograph.

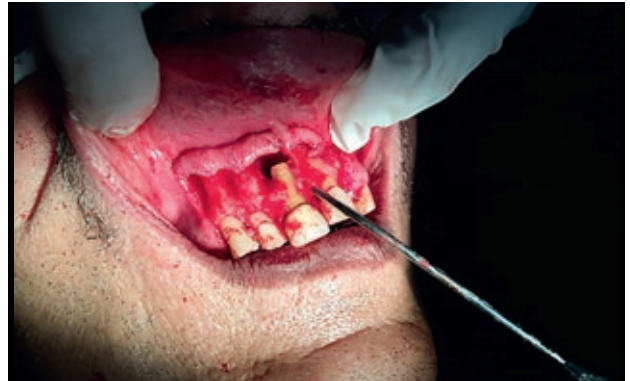

Fig. 25: Photograph during treatment.

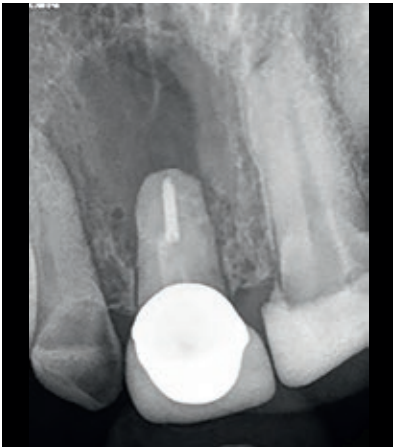

Fig. 26: Initial radiography 09-25-14.

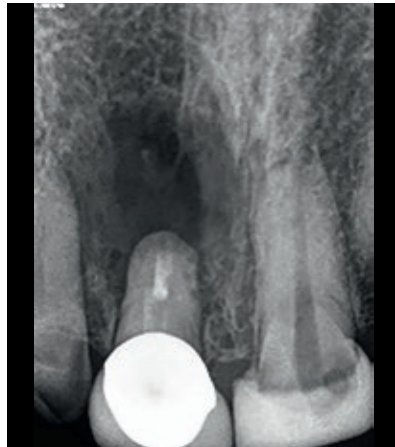

Fig. 27: Final radiography retro-filling with Biodentine™ 09-25-14.

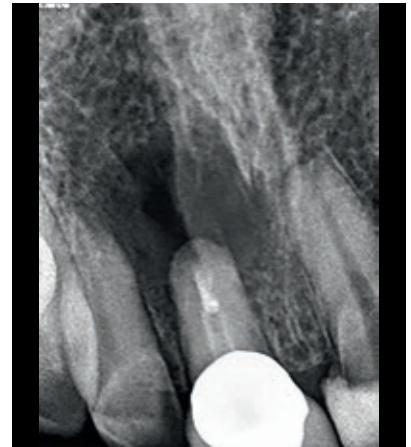

Fig. 28: First control 11-20-14 at 2 months.

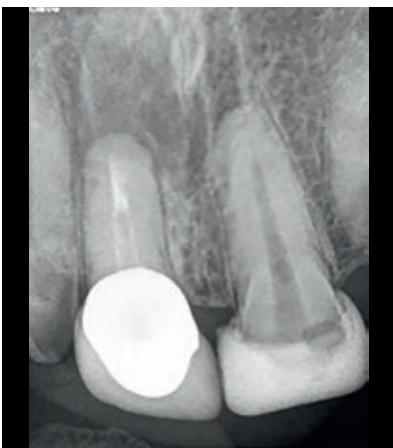

Fig. 29: Second control 05-20-1 at 8 months.

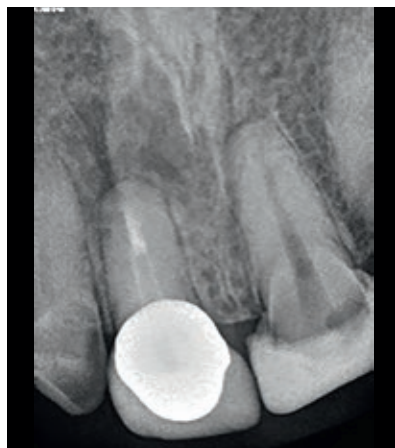

Fig. 30: Third control 11-27-15 at 1 year and three months.

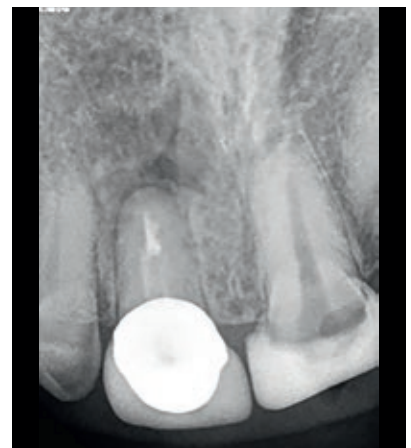
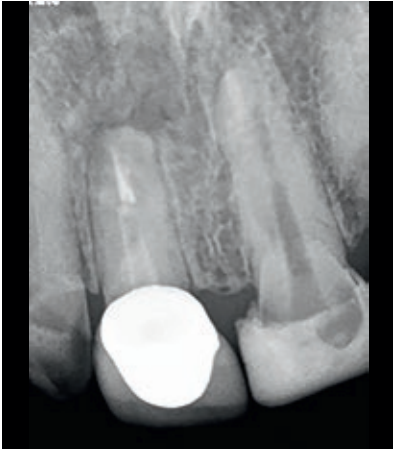
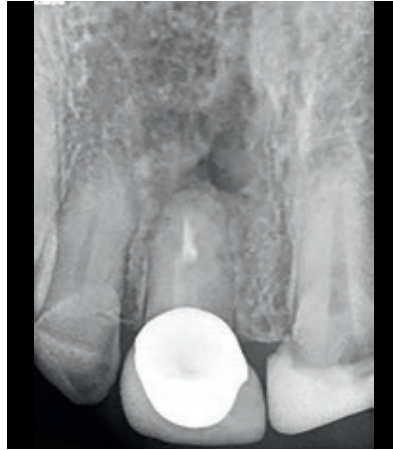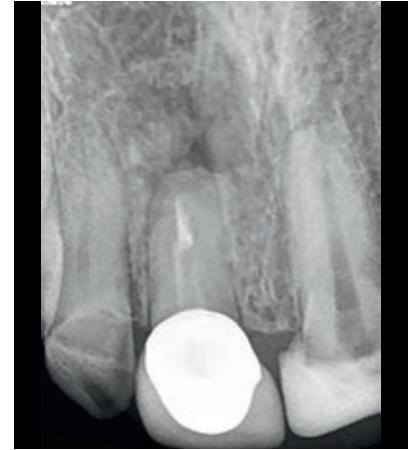Fig. 31: Fourth control 05-20-16 at 1 year and 9 months.



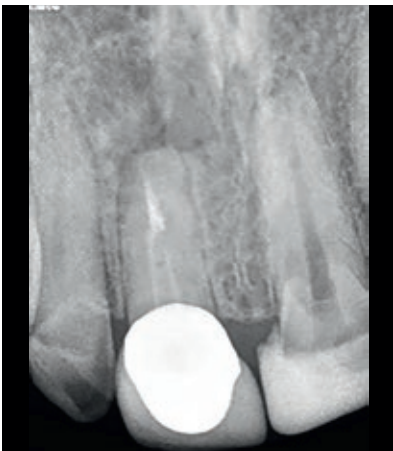*Fig. 32:* Fifth control 12-06-16 at 2 years and 4 months.



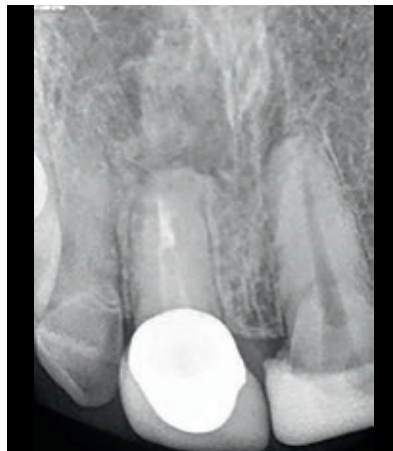
*Fig. 33:* Sixth control 03-31-17 at 2 years and 7 months.



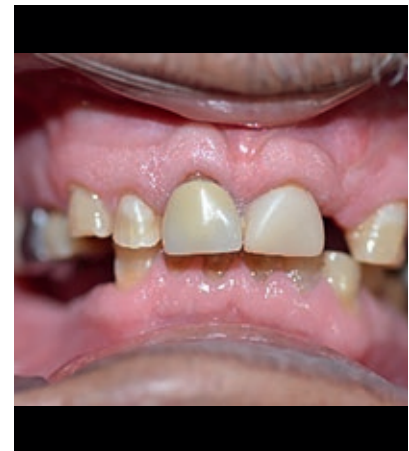*Fig. 34:* Seventh control 05-05-17 at 2 years and 8 months



*Fig. 35:* Eighth control 10-25-17 at 3 years and 1 month.



*Fig. 36:* Ninth control 04-25-2018 at 3 years and 7 months.



*Fig. 37:* Current photograph 04-25-2018 at 3 years and 7 months.

At the control at 3 years and 7 months, tooth 1.1 showed complete regeneration of the wound.

## Discussion

Amalgam has been used as a retro-filling material for many years. Its earliest use as a root filling after resection was recorded in 1884 (Vasudev 2003). It has the advantages of being easily available, economical and easy to handle. Years ago, amalgam was therefore considered as the material of choice for root fillings, and the clinical use of amalgam has been well documented in several clinical studies with a success rate ranging from 50% to 80% (Dalal 1983; Finne 1977; Grung 1990; Hirsch 1979; Persson 1974; Rud 1972).

In recent decades, amalgam has gradually given way to materials containing zinc oxide eugenol (ZOE), such as IRM, which comprises

20% in weight of polymethyl methacrylate added to sodium and poly ethoxy benzoic acid (Super-EBA), which contains ethoxy benzoic acid. Filtration in-vitro studies, animal studies and retrospective in vivo studies indicate that the materials containing ZOE are better than amalgam in terms of sealing and biocompatibility (Dorn 1990; Kim 2006; King 1990).

The shortcomings of cements currently available containing ZOE are mild to moderate toxicity when freshly mixed together and their radio-opacity which is similar to that of gutta-percha (Johnson 1999).

Mineral trioxide aggregate (MTA), developed at Loma Linda University, California, USA (Tora-

binejad 1993) has been the subject of much attention (Lee 1993). Its main constituents are similar to those of Portland cement, a mixture of dicalcium silicate, tricalcium silicate, tricalcium aluminate, gypsum and tetracalcium aluminoferrite (Camilleri 2005).

MTA offers major advantages including excellent biocompatibility (Camilleri 2006), ideal adherence with cavity walls, low solubility (Poggio 2007), and the ability to induce cementogenesis at the surface of the root, which is the deposit of new cement on the exposed dentin (Baek 2005). MTA is an excellent bioactive material. When placed in direct contact with human tissue, it forms calcium hydroxide which releases calcium ions for the union and proliferation of cells (Takita 2006); it modulates

the production of cytokines (Koh, 1998) and encourages the proliferation and migration of the parents followed by differentiation in odontoblast cells (Kuratate 2008).

However, the average setting time for MTA is  $165 \pm 5$  minutes, which is longer than amalgam, Super-EBA and IRM (Torabinejad 1995), something which is potentially problematic in endodontic surgery.

A new material, Biodentine™, possesses the reparative properties of dentin synthesis (Laurent 2012) with an initial setting time of 4 to 5 minutes and a final setting time of 10 to 12 minutes; its biocompatibility with regards the periapical tissues makes it a very useful material with ideal characteristics as a seal in retro-filling in apical microsurgery.

## References

---

- Kim S, Floratos S. Modern Endodontic Microsurgery Concepts: A Clinical Update. Dent Clin 2017 N Am (61)81–91.
- Kim S, Pecora G, Rubinstein R, editors. Color atlas of microsurgery in endodontics. Philadelphia: W.B. Saunders; 2001
- Cohen S, Burns R, editors. Pathways of the pulp. 6th edition. St Louis (MO): Mosby; 1994.
- Cohen S, Burns R, editors. Pathways of the pulp. 8th edition. St Louis (MO): Mosby; 2002. p. 683–721.
- Lubow RM, Wayman BE, Cooley RL. Endodontic flap design: analysis and recommendations for current usage. Oral Surg Oral Med Oral Pathol 1984;58(2): 207–12.
- Torabinejad M, Pitt Ford TR. Root end filling materials: a review. Endod Dent Traumatol 1996;12(4):161–78
- Biodentine™ - Publications and Communications 2005-2010. Research & Development Septodont, Paris 2010.
- Vasudev SK, Goel BR, Tyagi S. Root end filling materials A review. Endodontology 2003;15:12–8.
- Dalal MB, Gohil KS. Comparison of silver amalgam, glass ionomer cement & gutta percha as retrofilling materials, an in vivo & in vitro study. Journal of the Indian Dental Association 1983;55(4):153–8.
- Finne K, Nord PG, Persson G, Lennartsson B. Retro-grade root filling with amalgam and Cavit. Oral Surgery, Oral Medicine, and Oral Pathology 1977;43(4):621–6.
- Grung B, Molven O, Halse A. Periapical surgery in a Norwegian county hospital: follow-up findings of 477 teeth. Journal of Endodontics 1990;16(9):411–7.
- Hirsch JM, Ahlstrom U, Henrikson PA, Heyden G, Peterson LE. Periapical surgery. International Journal of Oral Surgery 1979;8(3):173–85.
- Persson G, Lennartson B, Lundström I. Results of retrograde root-filling with special reference to amalgam and Cavit root-filling materials. Swedish Dental Journal 1974; 67(3):123–34.
- Rud J, Andreasen JO, Jensen JE. Radiographic criteria for the assessment of healing after endodontic surgery. International Journal of Oral Surgery 1972;1(4):195–214.
- Dorn SO, Gartner AH. Retrograde filling materials: a retrospective success-failure study of amalgam, EBA, and IRM. Journal of Endodontics 1990;16(8):391–3.
- Kim S, Kratchman S. Modern endodontic surgery concepts and practice: a review. Journal of Endodontics 2006;32(7): 601–23.
- King KT, Anderson RW, Pashley DH, Pantera EA Jr. Longitudinal evaluation of the seal of endodontic retrofillings. Journal of Endodontics 1990;16(7):307–10.

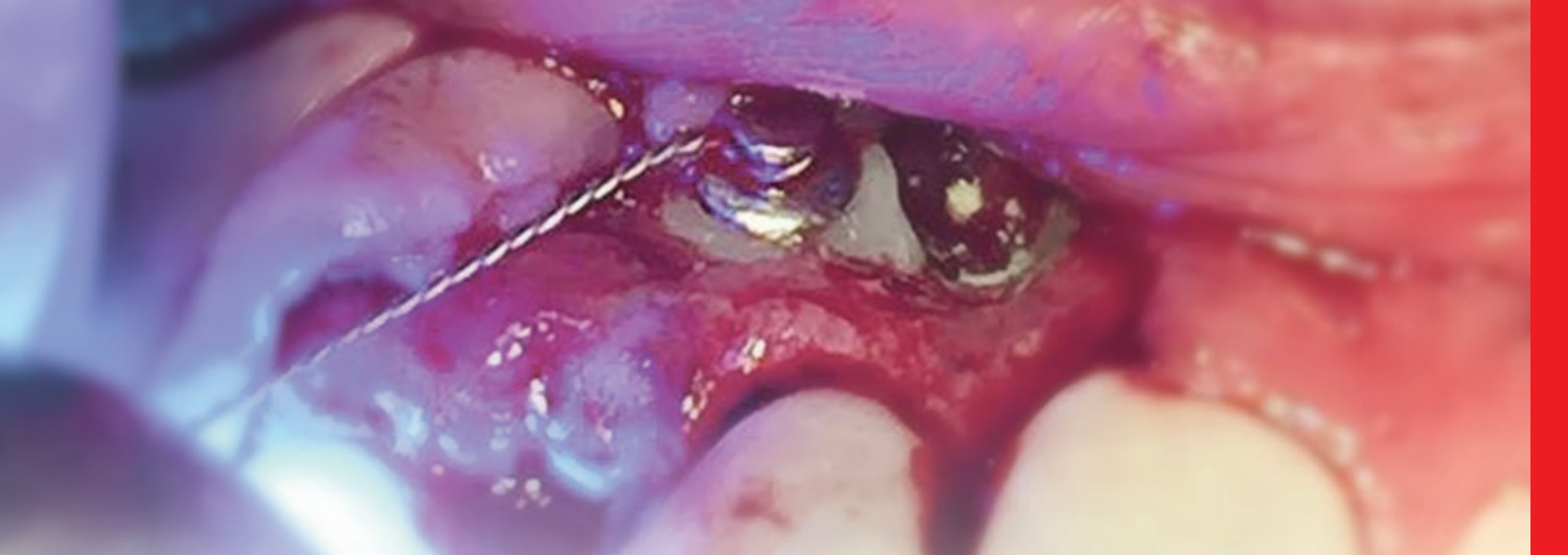
- Johnson BR. Considerations in the selection of a root-end filling material. Oral Surgery, Oral Medicine, Oral Pathology, Oral Radiology, and Endodontics 1999;87(4):398–404
- Torabinejad M, Watson TF, Pitt Ford TR. Sealing ability of a mineral trioxide aggregate when used as a root end filling material. Journal of Endodontics 1993;19(12):591–5. [PUBMED: 8151252]
- Lee SJ, Monsef M, Torabinejad M. Sealing ability of a mineral trioxide aggregate for repair of lateral root perforations. Journal of Endodontics 1993;19(11):541–4.
- Camilleri J, Montesin FE, Brady K, Sweeney R, Curtis RV, Ford TR. The constitution of mineral trioxide aggregate. Dental Materials 2005;21(4):297–303
- Camilleri J, Pitt Ford TR. Mineral trioxide aggregate: a review of the constituents and biological properties of the material. International Endodontic Journal 2006;39(10): 747–54
- Poggio C, Lombardini M, Conti A, Rindi S. Solubility of root-end filling materials: a comparative study. Journal of Endodontics 2007;33(9):1094–7.
- Baek SH, Plenck H Jr, Kim S. Periapical tissue responses and cementum regeneration with amalgam, SuperEBA, and MTA as root-end filling materials. Journal of Endodontics 2005;31(6):444–9
- Takita T, Hayashi M, Takeichi O, Ogiso B, Suzuki N, Otsuka K, et al. Effect of mineral trioxide aggregate on proliferation of cultured human dental pulp cells. International Endodontic Journal 2006;39(5):415–22
- Koh ET, McDonald F, Pitt Ford TR, Torabinejad M. Cellular response to Mineral Trioxide Aggregate. Journal of Endodontics 1998;24(8):543–7.
- Kuratate M, Yoshiba K, Shigetani Y, Yoshiba N, Ohshima H, Okiji T. Immunohistochemical analysis of nestin, osteopontin, and proliferating cells in the reparative process of exposed dental pulp capped with mineral trioxide aggregate. Journal of Endodontics 2008;34:970
- Torabinejad M, Hong CU, McDonald F, Pitt Ford TR. Physical and chemical properties of a new root-end filling material. Journal of Endodontics 1995;21(7):349–53.

Download the complete series

# Septodont Case Studies Collection

[www.septodont.com](http://www.septodont.com)





# Multidisciplinary management of an external communicating resorption caused by the ectopic eruption of a maxillary canine

Maximiliano Casa, H; Alfredo Sierra, C.

## Introduction

Root resorption is the decomposition, destruction and subsequent loss of the dental root structure. Root resorption caused by odontoclasts during the exfoliation of the deciduous teeth is a natural process that leads to the eruption of the permanent teeth. However, resorption can also occur in the permanent dentition due to trauma, excessive occlusal load, cysts, tumors, orthodontic treatments and ectopic eruption of adjacent teeth (Hadler-Olsen et al., 2015).

The ectopic eruption is defined as the abnormal position of the tooth, which alters its eruptive trajectory and leads to its impaction against the adjacent tooth. After the third molars, the canines are the teeth that present the most anomalies in their eruption, being trapped in the bone can produce complications such as displacement of the teeth, loss of vitality of the adjacent incisors, shortening of the dental arch, formation of follicular cysts, canine ankylosis, recurrent infections, recurrent pain, internal resorption, external resorption of the canine and adjacent teeth, or combinations of these factors (Alqerban,

Jacobs, Lambrechts, Loozen & Willems, 2009). The prevalence of ectopic eruption of maxillary canines is 1 - 3%. It is more frequent in women than in men and it has been reported that 50% of the cases of root resorption of the maxillary lateral and maxillary incisors occur as an adverse effect. (Alqerban, Jacobs, Fieuws & Willems, 2011). The canine, and the maxillary lateral and maxillary incisors are located in an area of high aesthetic and functional demand, so it is important to carry out a diagnosis and early intervention, which allow us to generate therapeutic strategies that can improve the prognosis of affected parts and minimize possible sequels. The root reabsorption of the lateral incisor can be diagnosed radiographically at an early stage, but the resorption process can remain asymptomatic, even in cases in which the pulp is affected (Ericson & Kuroi, 1987). When the diagnosis occurs at an advanced stage, it is difficult to define the treatment and prognosis, and it may lead to the extraction of the affected tooth. For the sealing and restoration of root resorption,

various materials have been used, such as: calcium silicate-based cements such as mineral trioxide aggregate (MTA), glass ionomer cement, calcium enriched mixture, etc. The MTA (ProRoot MTA, Dentsply, Tusa, OK USA) developed by Torabinejad and Contributors, is a bioactive material that since the early nineties has been used for various applications in endodontics. The MTA is indicated to restore defects of internal and external resorptions, horizontal root fractures, sealing of perforations, pulp therapy in permanent and deciduous teeth, apical sealing of the root canal in teeth with mature and immature apices. It has been shown that MTA is biocompatible, stimulates mineralization and promotes crystalline deposits similar to apatite (Güzeler I & Uysal S., 2010, Tomás-Catalá CJ et al., 2018). Taking as a reference the properties of the MTA, Biodentine™ (Septodont, Saint-Maur-des-Fosses, France) was developed, a material based on calcium silicate, which may be a valid option as it acts as a substitute for dentin, of

antibacterial action, of which no cytotoxicity, genotoxicity or mutagenicity have been reported. When compared to the MTA it presents better physical and biological properties, better handling, adherence, fast setting time, greater resistance to compression, early synthesis of reparative dentin. Its powdered components are tricalcium silicate, dicalcium silicate, and calcium carbonate as filler and zirconium oxide acting as radiopacifier; on the other hand, the liquid component contains calcium chloride, water and a reducing agent (Cernochova P et al., 2011, Baranwal AK et al., 2016, Al-Haddad A et al., 2016, Eftekhari L et al., 2017, Sultana N et al., 2018).

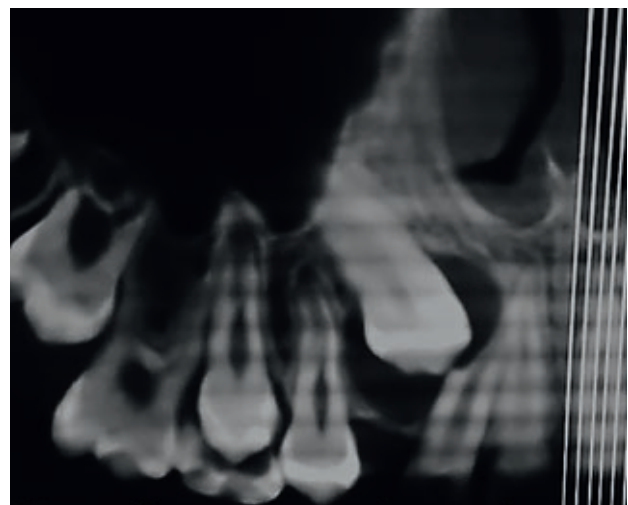In the present case we describe the management of external communicating resorption of the upper left lateral incisor, caused by the ectopic eruption of the left upper canine, by using Biodentine™ as a sealant for the sequel and subsequent rehabilitation with a fiberglass post. and light curing resin.

## Clinical case report

Female patient, 12 years old, ASA I. The patient was referred by a pediatric dentist colleague. Radiographically the tooth 1.3 is retained from intra-osseous form, impacted on the distal area of the root of the tooth 1.2, generating an external cementum resorption, it can also be observed that the periodontal ligament of tooth 1.2 has slightly thickened (*Fig.1*). Clinically, the patient presents absence of tooth 1.3 and asymptomatic 1.2, which sensitivity tests respond positively to both heat and cold and negative to percussion and palpation.

The following diagnoses were made: tooth number 1.2; vital pulp with external cementum resorption that shows a communication between the periodontium and the pulp tissue and tooth number 1.3; impacted in the distal middle third of the root of tooth 1.2, being retained by it intraosseously in the maxilla.

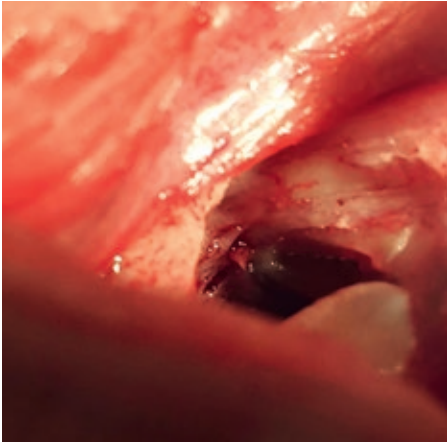
A multidisciplinary Treatment Plan was proposed. The objectives of this proposal are firstly the




*Fig. 1:* Initial tomography, where it can be observed that external cementum resorption shows a communication between the periodontium and the pulp canal.

cleaning, shaping and sealing of the root canal system, the sealing of the perforations in the root and later, positioning the tooth 1.3 inside the dental arch and thus return its functionality. We divide it into the following stages:

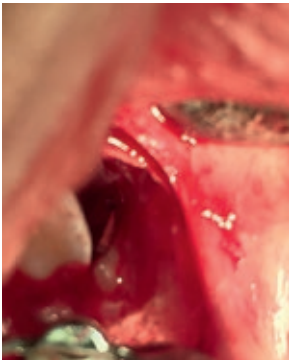
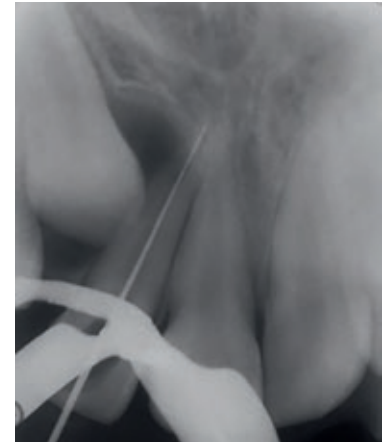
1. Surgical resorption approach.
2. Partial biopulpectomy 1.2.
3. External resorption surgical seal.
4. Rehabilitation of tooth 1.2.
5. Orthodontic traction of tooth 1.3.



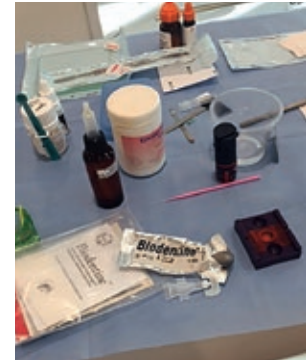
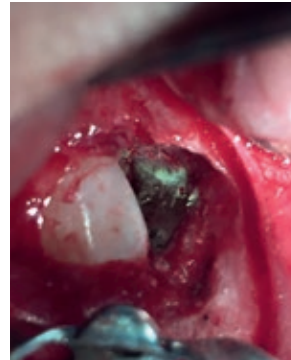**Fig. 2:** Surgical access to the area of resorption, where the passage of the file is observed when removing the granulation tissue present in the resorption.



**Fig. 3:** (a) Removal of the dental pulp, demonstrating that the dental organ was totally vital. (b) Odontometry, In this case it was not possible to perform it with the LAE (electronic apex locator) due to the false positive that it was throwing in the area of the resorption. Therefore, it was done using the radiographic method.



**Fig. 4:** (a) Once the channel was prepared with Protaper Next files, the appropriate gutta-percha cone was chosen and then cut with the Touch and Heat technique and thus sealing the apical third with the single cone technique and (b) BioRoot™ RCS Cement by Septodont.



**Fig. 5:** (a) Once the apical third was sealed, the external resorption was sealed using a bioceramic (b), which on this occasion was the Biodentine™.

The maxillo-facial surgeon, following the previously established work plan, begins anesthetizing the area with an infiltrative technique, to subsequently make a Newman type flap from the distal side of tooth 1.4 to the mesial side of tooth 1.1, accessing and clearing the area of resorption for further treatment (*fig. 2*).

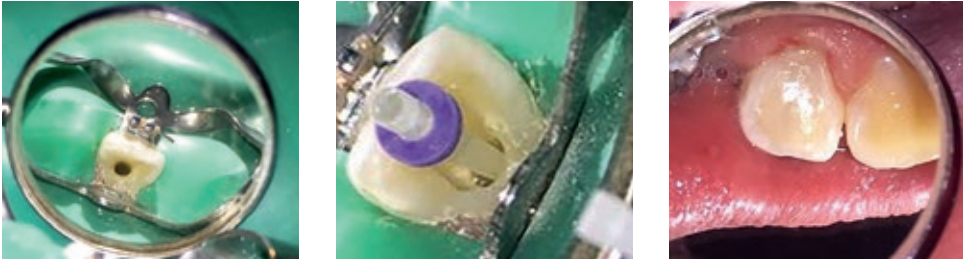Then the endodontist, after absolute isolation, performs the endodontic access from the palatal tooth piece 1.2, linking the apical and cervical third, through the external cement reabsorption shown in figure 2. The channel is prepared chemically and mechanically, with the Protaper Next (Dentsply-Maillefer rotary system, Ballaigues, Switzerland), irrigating with the technique of negative apical pressure with abundant 2.5% sodium hypochlorite, then drying the canal with sterile paper tips, sealing the apical third with the technique of the single cone (gutta percha 6%) and BioRoot™ RCS

(Septodont, Saint-Maur-des-Fosses, France), a bioceramic-based cement.

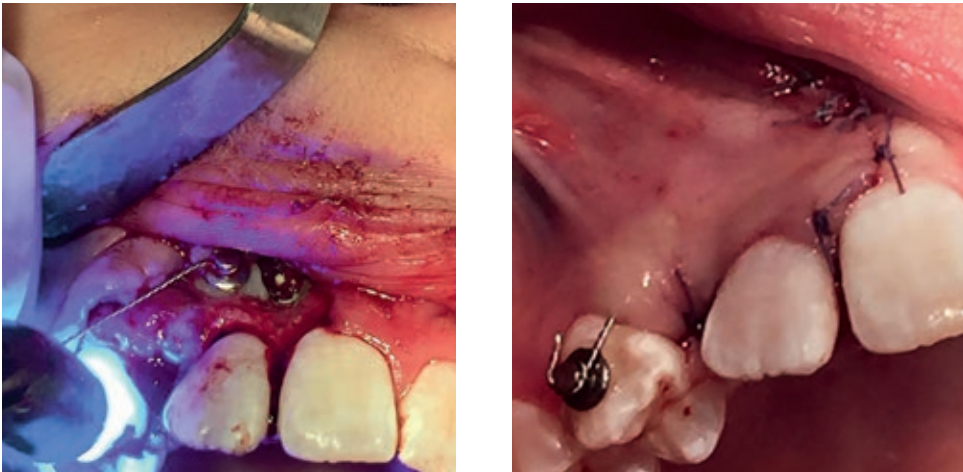
In this way, through the surgical access, the apical third of the canal is sealed, dedicating efforts to reconstruct with Biodentine™ the defect caused by cemental resorption (*Fig. 4, 5*).

Once the defect is reconstructed, the remaining thirds and endodontic access are rehabilitated, cementing a fiberglass pole (Relyx Fiber Post of 3MESPE), with cement (RelyXU200), acid etching (3M ESPE Scotchbond) and adhesive (3M) ESPE Single Bond Universal) with light curing resin (Filtex Z350 XT of 3M ESPE), giving the tooth the necessary flexion to rejoin the stomatognathic system without problems (*fig. 6*).

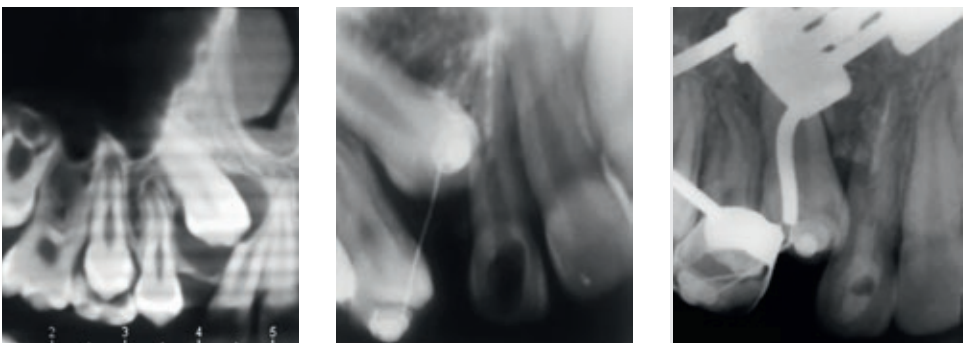
Finally, the orthodontist intervenes, placing the additives to begin with the orthodontic surgical detachment of the dental piece 1.3 towards the corresponding place in the arch, following the initial planning (*Fig. 7*).



**Fig. 6:** (a) Taking advantage of the control of the sterile area, it is decided to permanently seal the cervical and middle third with (b) fiber post Relyx Fiber Post, and cement RelyX U200, acid etching with 3M ESPE Scotchbond and application of adhesive Single Bond Universal. (c).

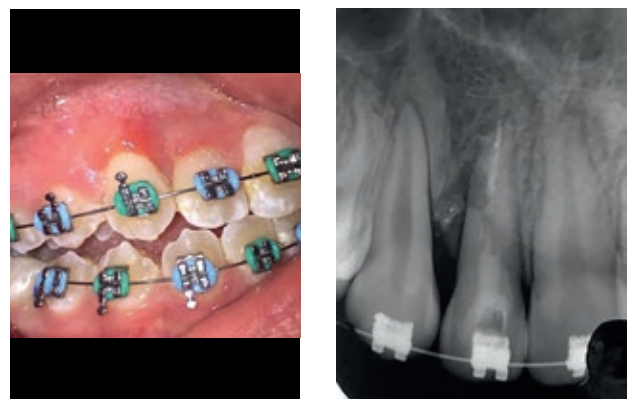


**Fig. 7:** (a) Placement of the attachments, to begin with the pulling of tooth 1.3. (b) closure of the flap by the surgeon, terminating the surgical procedure.



**Fig. 8:** (a) Initial radiography. (b) Immediate postoperative radiograph. (c) X-ray of the 1-year control.

By way of summary in Figure 8 the radiographic evolution of the case is shown. (*Fig. 8a*) Initial X-ray, where it could be presumed that the cementum resorption opened a communication path between the periodontium and the pulp canal. (*Fig. 8b*) Immediate postoperative image: the apical third and the obturation of the external cemental resorption are observed and (*Fig. 8c*) controlled one year after the surgery, the sealing of the canal is clearly observed in the apical third, as well as the repair of the bone tissue and finally the ongoing displacement of the canine. The favorable evolution was observed in the last clinical and radiographic control completed 2 years after the surgical therapy (*Fig. 9*). Both teeth involved are asymptomatic and fully functional.



**Fig. 9:** (a) Clinical (b) and radiographic control 2-year follow-up of the surgical therapy.



# Discussion

The treatment of cementum resorption generates, until today, different opinions among endodontists, orthodontists, rehabilitators, implantologists, clinicians and scientists (Güzeler I & Uysal S., 2010, Alqerban, Jacobs, Fieuws & Willems., 2011, Umashetty G et al., 2015, Baranwal AK et al., 2016, Eftekhar L et al., 2017).

Local and general factors are related to the impact of higher permanent canines and to the reabsorption that this causes, such as; traumas, prolonged retention or premature loss of the primary canine, agenesis or alteration in the form of lateral incisors, chronic inflammation of the pulp, periodontal tissues or both, abnormal position of the dental germ, localized pathology such as cysts, neoplasms, odontomas and supernumeraries, ankylosis, idiopathic origin, slow-growing tumors such as giant cell tumors, osteosclerosis and other fibro-osseous lesions, iatrogenic, naso-respiratory problems, variation in the size of the tooth root, variation in the time of root formation, sequence of abnormal eruption, systemic diseases (hyperparathyroidism), narrow arch form, immune factors and inheritance, (Fuss., et al 2003, Alqerban, Jacobs, Fieuws & Willems., 2011, Gunraj MN., 1999).

It is very important then to foresee when there will not be enough space in the arcade for the eruption of the permanent teeth, since their pressure on others will cause in a not lesser percentage, some degree of reabsorption. This can cause their loss. The treatment plan that will be carried out in a dental piece that contains a communicating cementum resorption is very different from that in which it is not present (Roscoe MG., Et al 2015). The biological consequences are diametrically different, the first being, the worst prognosis. Since it is not possible to treat only the communicating cementum resorption without producing a significant damage in the pulp tissue, forcing to plan a joint pulpal treatment. However, the evolution of those reabsorptive treatments that do not show communication between the periodontium and the endodontium, only

relate to the treatment that is approached from the periodontium, allowing the pulp to remain healthy and undamaged.

The planning and consensus among the different professionals that should intervene in the treatment of these pathologies, is a challenge. Especially, when a few years ago, the dentist was confined to his practice trying to perform all procedures without any collaboration. Currently this type of thinking would be untimely as the multidisciplinary work is indicated so that each specialist develops the treatment of their specialty, providing the patient with the quality of their treatment and the opportunity to keep the teeth in the mouth, functional and healthy.

Surgical access to address the resorption zone is well described in the literature and depending more on the clinical or anatomical characteristics of the area to be treated, there are no major discrepancies (McDonald F & Yap WL., 1986, Caminiti MF et al., 1998, Chapokas AR et al., 2012, Becker A & Chaushu S., 2015). These begin at the moment in which we initiate the endodontic treatment and we have to decide which concentration of hypochlorite, which type of file and the last number we'll use, which filling technique and material with which we will reconstruct the reabsorbed area (Brunson M et al., 2010). Finally, the biggest question, will this therapy succeed?

With respect to irrigation, it is clear that hypochlorite was used and that the lower its concentration, the lower the effects, which can be compensated with a frequent and abundant flush. (Regan JD & Fleury AA., 2006, Van Der Sluis L, 2006, Cohenca N et al., 2010, Haapasalo M., 2014). Therefore we could use 1.5% hypochlorite; 2.5% or 5.25% and get similar results. Regarding the last instrument to be used, it is well documented that the larger the diameters used, the greater the number of microorganisms removed, allowing an adequate cleaning with sodium hypochlorite thanks to the access with irrigation and aspiration tips (LG Coldero., 2002, Card SJ.,

2002 Brito PRR., 2009). In this case, in which the reabsorption occurs on the external face of the root at the level of the curvature in the apical third, there are anatomical and physical characteristics that prevent a common irrigation as anatomically normal canals have accustomed us. For that reason, it was chosen in order to clean the canal, to divide it into two portions. One, from the cameral access to the cervical edge of the reabsorption (extra surgical portion) and the second, from the apical end of the reabsorption to the apex (intra-surgical portion). In both situations, the irrigation technique with negative apical pressure was used to minimize the possibility of extravasation of the irrigant to the periodontium (Goldman M et al., 1998, Mehdipour O et al., 2007, Cohenca N et al., 2010)

Taking into account the previously described and thanks to the location of the resorption and anatomy of the root, it was possible to use the Protaper Next rotary system to shape the canal. Properly protecting the alveolus from the inclemency of the different materials used, it was decided to seal the canal with the use of a single gutta-percha cone with increased taper, cemented with a bioceramic-based cement such as BioRoot™ RCS, to be subsequently cut with the Touch and Heat system. In this way,

we seal the apical third and dedicate ourselves to reconstruct the space left by the cemental resorption.

Again, we find different opinions about the material to be used for this purpose (Luo T et al., 2018, Umashetty G et al., 2015, Baranwal AK et al., 2016, Eftekhar L et al., 2017). With the advent of bioceramics, taking advantage of the fact that the canal was filled with a cement with the same chemical characteristics, it was decided to seal the resorption with another bioceramic, Biodentine™. This one has ideal chemical and physical characteristics, which makes it the material of choice, durable, with a flexural index similar to that of dentin, with an adequate setting time, biocompatible and bioactive among other characteristics (Cernochova P et al., 2011, Baranwal AK et al., 2016, Al-Haddad A et al., 2016, Eftekhar L et al., 2017, Sultana N et al., 2018).

Once the defect caused by the resorption was reconstructed, it was decided to rehabilitate the remaining third and the endodontic access, cementing it with a fiberglass pole and nanoparticle resin, providing the tooth with the flexion, resistance and esthetics needed to incorporate it. Stomatognathic system without drawbacks.

## Conclusion

There will always be criteria to take into account to decide the clinical procedures in these therapies. However, there is no conclusive study that supports a single treatment that gives us success without exception in all cases. On the other hand, if there is scientific evidence that would support each of the steps we carry out separately, leaving it up to us, to compromise to fill those missing spaces, rigorously complying with the different protocols and deciding in each case, the most appropriate to follow.

The discovery of these traumatic sequelae

is always a radiographic finding with clinical clues, therefore it is important to prevent and avoid adverse sequelae. For this purpose, a protocol for timely review should be implemented, including radiographic follow-up, assessments of abnormal anatomical features such as the absence of canine eminence, among others.

Last, but not least, remember the importance of forming multidisciplinary work teams that provide the vision of each of the specialties in decision making in cases of high complexity.

## Authors:



### Maximiliano Casa Herzmann

Dentist, National University of La Plata, Buenos Aires, Argentina, 1996.

Dental surgeon. University of Chile, 2005.

Specialist in Endodontics 2006, (CONACEO)

21 years of experience as a teacher in the training of pre and post graduates in the Department of Endodontics and Pediatric Dentistry in National and International Universities.

Author and co-author of practical work guides in the area of Endodontics and Pediatric Dentistry.

Exhibitor of seminars, courses and congresses in national and international media.

Active member in the Endodontics Society of Chile.

Private professional practice 20 years ago.

Coordinator of the area of conservative treatments in Permanent Teeth Young, in the department of Integral of the child I and II in the Autonomous University of Chile.

Co-author of the book "Clinical Guide and Text of Endodontics", (in process of edition 2018).

Contact; Orphans 1044, office 82, CP: 8320000,

telephone: +569226886979 / +56922334585 - mcase@paisdental.cl



### Alfredo Sierra Cristancho

Dentist - University of Cartagena (Colombia). Specialist in Endodontics Andrés Bello University (Chile). Magister in Dental Sciences University of Chile.

## References

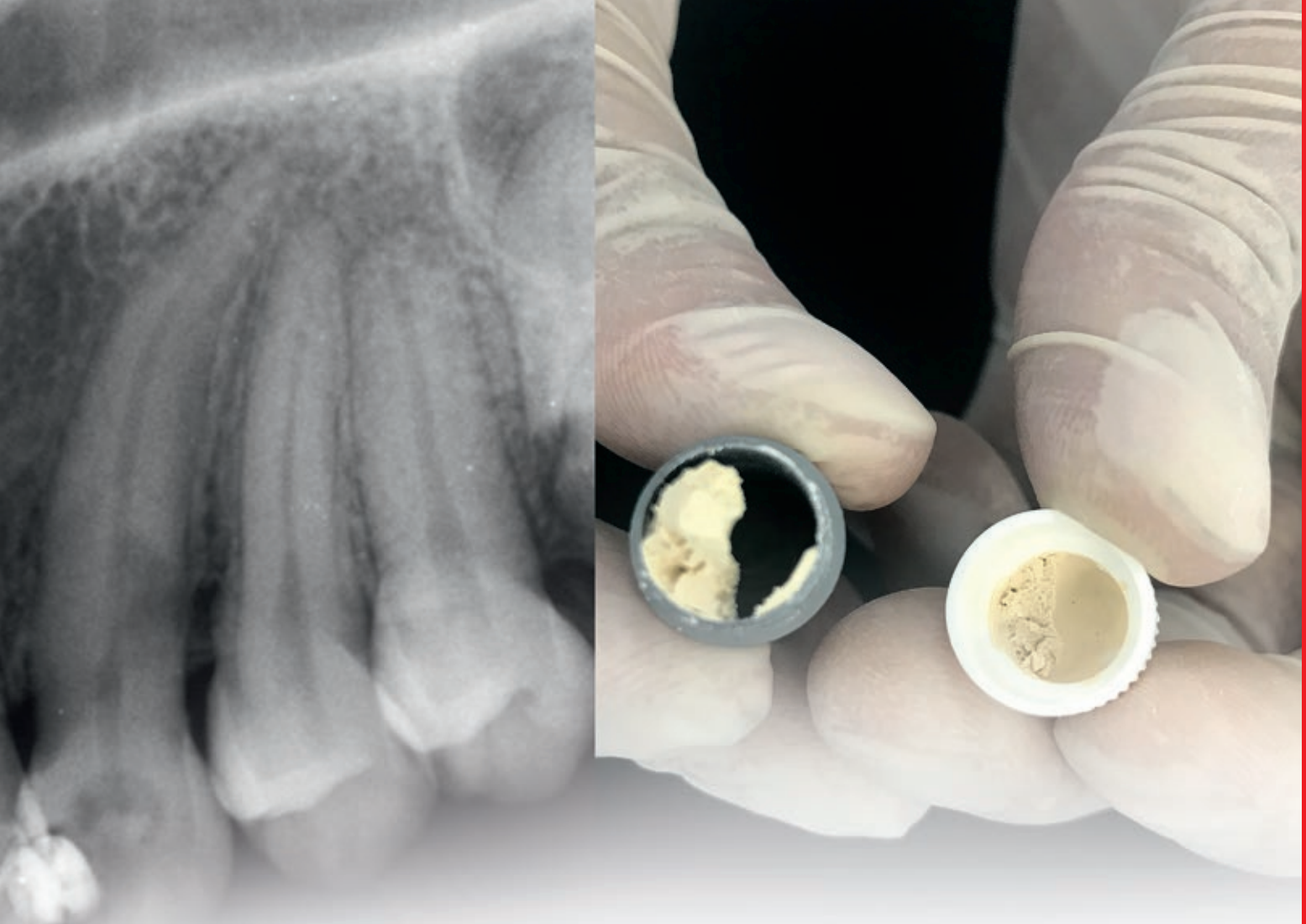---

1. Al-Haddad A, Che Ab Aziz ZA. Bioceramic-Based Root Canal Sealers: A Review. *Int J Biomater*. 2016. Epub 2016 May 3.
2. Alqerban, A., Jacobs, R., Lambrechts, P., Loozen, G., & Willems, G. (2009). Root resorption of the maxillary lateral incisor caused by impacted canine: a literature review. *Clinical Oral Investigations*, 13(3), 247-255.
3. Alqerban, A., Jacobs, R., Fieuws, S., & Willems, G. (2011). Comparison of two cone beam computed tomographic systems versus panoramic imaging for localization of impacted maxillary canines and detection of root resorption. *The European Journal Of Orthodontics*, 33(1), 93-102.
4. Baranwal AK. Management of external invasive cervical resorption of tooth with Biodentine™: A case report. *J Conserv Dent*. 2016 May-Jun;19(3):296-9.
5. Becker A, Chaushu S. Surgical Treatment of Impacted Canines: What the Orthodontist Would Like the Surgeon to Know. *Oral Maxillofac Surg Clin North Am*. 2015 Aug;27(3):449-58.
6. Brunson M, Heilborn C, Johnson J, Cohenca N. Effect of Apical Preparation Size and Preparation Taper on Irrigant Volume Delivered by Using Negative Pressure Irrigation System. *Journal of Endodontics* 2010; 36: 721-724.
7. Brito PRR, Souza LC, Machado de Oliveira JC, Alves FRF, De-Deus G, Lopes HP, et al. Comparison of the effectiveness of three irrigation techniques in reducing intracanal *Enterococcus faecalis* populations: an in vitro study. *Journal of endodontics*. 2009 Oct; 35(10):1422-7.
8. Caminiti MF, Sandor GK, Giambattistini C, Tompson B. Outcomes of the surgical exposure, bonding and eruption of 82 impacted maxillary canines. *J Can Dent Assoc*. 1998 Sep;64(8):572-4, 576-9.

## References

---

9. Card SJ, Sigurdsson A, Orstavik D, Trope M. The effectiveness of increased apical enlargement in reducing intracanal bacteria. *J Endod.* 2002 Nov;28(11):779-83.
10. Cernochova P, Krupa P, Izakovicova-Holla L. Root resorption associated with ectopically erupting maxillary permanent canines: a computed tomography study. *Eur J Orthod.* 2011 Oct;33(5):483-91.
11. Cohenca N, Heilborn C, Johnson D, Silva D, Flores H, Yoko I, Bezerra L. Apical negative pressure irrigation versus conventional irrigation plus triantibiotic intracanal dressing on root canal disinfection in dog teeth. *Oral Surg Oral Med Oral Pathol Oral Radiol Endod* 2010; 109: 42- 46.
12. Coldero LG, McHugh S, MacKenzie D, Saunders WP. Reduction in intracanal bacteria during root canal preparation with and without apical enlargement. *Int Endod J.* 2002 May;35(5):437-46.
13. Chapokas AR, Almas K, Schincaglia GP. The impacted maxillary canine: a proposed classification for surgical exposure. *Oral Surg Oral Med Oral Pathol Oral Radiol.* 2012 Feb;113(2):222-8.
14. Ericson, S., & Kuroi, J. (1987). Radiographic examination of ectopically erupting maxillary canines. *American Journal Of Orthodontics And Dentofacial Orthopedics*, 91(6), 483-492.
15. Eftekhar L, Ashraf H, Jabbari S. Management of Invasive Cervical Root. Resorption in a Mandibular Canine Using Biodentine™ as a Restorative Material: A Case Report. *Iran Endod J.* 2017 Summer;12(3):386-389.
16. Fuss Z, Tsesis I, Lin S. Root resorption--diagnosis, classification and treatment choices based on stimulation factors. *Dent Traumatol.* 2003 Aug; 19(4):175-82.
17. Goldman M, White RR, MoserCR, Tenca JI. A comparison of three methods of cleaning and shaping the root canal in vitro. *J Endodon* 1988; 14:7-12.
18. Gunraj MN. Dental root resorption. *Oral Surg Oral Med Oral Pathol Oral Radiol Endod.* 1999 Dec; 88(6):647-53.
19. Güzeler I, Uysal S, Cehreli ZC. Management of trauma-induced inflammatory root resorption using mineral trioxide aggregate obturation: two-year follow up. *Dent Traumatol.* 2010 Dec;26(6):501-4.
20. Hadler-Olsen, S., Pirttiniemi, P., Kerosuo, H., Bolstad Limchaichana, N., Pesonen, P., Kallio-Pulkkinen, S., & Lähdesmäki, R. (2015). Root resorptions related to ectopic and normal eruption of maxillary canine teeth – A 3D study. *Acta Odontologica Scandinavica*, 73(8), 609-615.
21. Haapasalo M, Shen Y, Wang Z, Gao Y. Irrigation in endodontics. *Br Dent J.* 2014 Mar;216(6):299-303.
22. Luo T, Liu J, Sun Y, Shen Y, Zou L. Cytocompatibility of Biodentine™ and iRoot FS with human periodontal ligament cells: an in vitro study. *Int Endod J.* 2018 Jan 19.
23. McDonald F, Yap WL. The surgical exposure and application of direct traction of unerupted teeth. *Am J Orthod.* 1986 Apr;89(4):331-40.
24. Mehdipour O, Kleier D, Averbach R. Anatomy of sodium hypochlorite accidents. *Compend Contin Educ Dent* 2007; 28: 544-6.
25. Regan JD, Fleury AA. Irrigants in non-surgical endodontic treatment. *J Ir Dent Assoc.* 2006 Autumn;52(2):84-92.
26. Roscoe MG, Meira JB, Cattaneo PM. Association of orthodontic force system and root resorption: A systematic review. *Am J Orthod Dentofacial Orthop.* 2015. May;147(5):610-26.
27. Sultana N, Singh M, Nawal RR, Chaudhry S, Yadav S, Mohanty S, Talwar S. Evaluation of Biocompatibility and Osteogenic Potential of Tricalcium Silicate-based Cements Using Human Bone Marrow-derived Mesenchymal Stem Cells. *J Endod.* 2018 Mar; 44(3):446-451.
28. Tomás-Catalá CJ, Collado-González M, García-Bernal D, Oñate-Sánchez RE, Forner L, Llena C, Lozano A.
29. Moraleda JM, Rodríguez-Lozano FJ. Biocompatibility of New Pulp-capping Materials NeoMTA Plus, MTA Repair HP, and Biodentine™ on Human Dental Pulp Stem Cells. *J Endod.* 2018 Jan;44(1):126-132.
30. Umashetty G, Hoshing U, Patil S, Ajgaonkar N. Management of Inflammatory Internal Root Resorption with Biodentine™ and Thermoplasticised Gutta-Percha. *Case Rep Dent.* 2015;2015:452609.
31. Van Der Sluis LWM, Gambarini G, Wu MK, Wesselink PR. The influence of volume, type of irrigant and flushing method on removing artificially placed dentine debris from the apical root canal during passive ultrasonic irrigation. *International Endodontic Journal.* 2006; 39(6):472-476.



# Root reconstruction with Biodentine™.

Tenorio Fernando, Campos Paola, Mancera Navarro Ana Karen.

## | Summary

Cervical inflammatory resorption is associated with mechanical and biological factors. One of its underlying causes is periodontal disease, and its diagnosis is usually made by means of periapical radiographs or CBTC, because the teeth remain vital.

Case Study. Female patient, presenting caries and periodontal disease; upon inspection, tooth 23 presents a radiolucent zone, and a diagnosis made via CBTC of external cervical

resorption greater than 4mm having no communication with the root canal; reconstruction performed using Biodentine™, and clinical success observed at 3, 6, and 15 months after placement.

Conclusion. The use of tricalcium silicate-based cements such as Biodentine™ provides a guarantee of low toxicity, excellent sealing, and biocompatibility.

# Introduction

Cervical inflammatory resorption, extra-canal invasive resorption, and cervical inflammatory resorption [sic] are terms used to describe a particular form of external resorption, i.e., dentin-cementum resorption; this is a disorder that has been observed with increasing frequency, associated with two types of predisposing factors, mechanical and biological.<sup>1</sup> Such mechanical factors may include traumatism, orthodontic forces, or prosthetic forces; as for the biological factors, they are associated with systemic diseases, genetic and immunological susceptibility, infectious processes, dental impaction, dental reimplantation and periodontal disease, with no determination of exact etiology; the authors have classed this disorder among conditions involving inflammatory resorption developing cervical lesions above the crestal bone (supraosseous) or below the crestal bone (intraosseous).<sup>2-4</sup>

The diagnosis is usually determined as a radiographic finding, with an observation of radio-

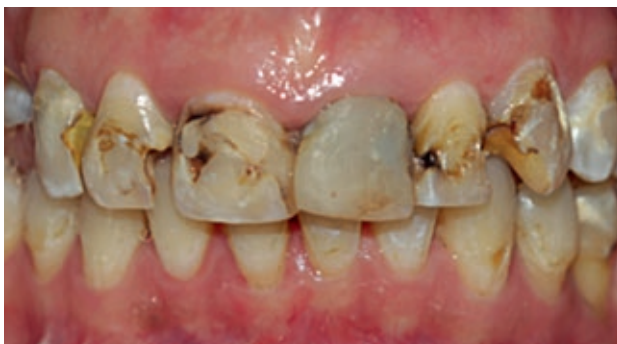lucency in the root periphery, since patients do not regularly present symptoms, i.e., if a pulp sensitivity test is performed, a normal reaction will be observed.<sup>1,6,7</sup>

Tricalcium silicate-based cements have been developed for use in root canal treatments, apexifications, retrograde fillings, and repair procedures for internal and/or external resorption, for the purpose of obtaining materials combining antimicrobial activity and good sealing capacity.<sup>8,9</sup> The components of a tricalcium silicate cement such as Biodentine™ (Septodont, France) include a water-based liquid component, calcium chloride as a setting accelerator, and a water-soluble polymer (polycarboxylate), which provides good fluidity.<sup>10</sup> Like MTA, Biodentine™ also features tissue compatibility, bioactivity and compressive strength.<sup>11</sup> Although both materials are tricalcium silicate-based, Biodentine™ does not contain aluminate, which shortens its setting time and helps prevent potential health risks.<sup>12</sup>

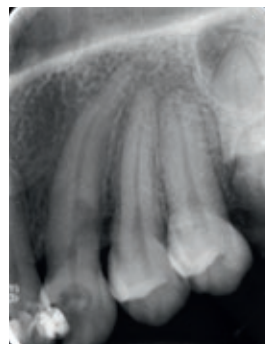
# Clinical case study

Female patient, twenty-seven years of age, visiting the endodontics clinic of the ENES León Unit at the UNAM due to multiple carious lesions (*Fig. 1*); the radiographic examination showed a radiolucent area in tooth 23 at the cervical third of the root (*Fig. 2*) CBCT of the area

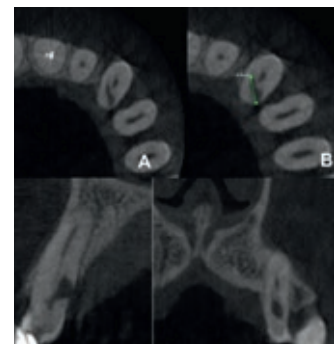was requested, which showed an oval shaped external resorption 4 mm in diameter (*Fig. 3*) having no communication with the root canal; the decision was thus made to perform root reconstruction using Biodentine™ (Septodont, France).



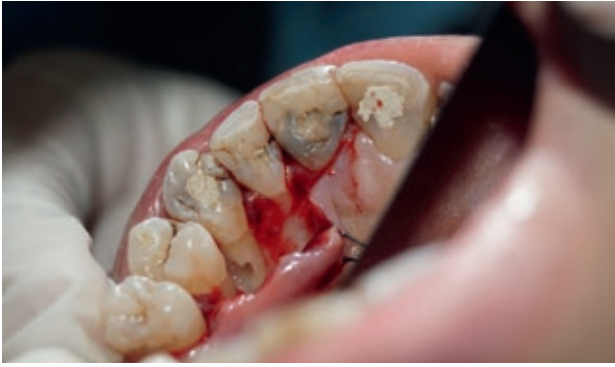*Fig. 1:* Initial clinical photograph of the patient.



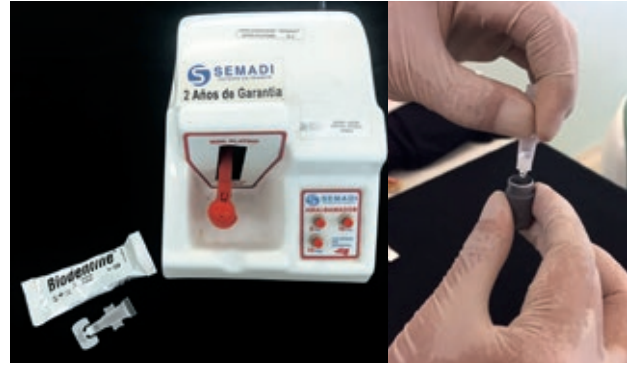*Fig. 2:* Diagnostic radiography.



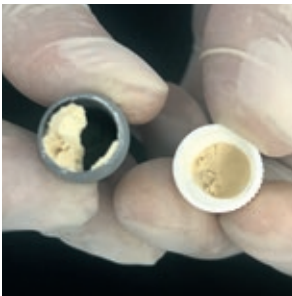
*Fig. 3:* CBCT (A) Cross-section, (B) Extraction of the resorption of approximately 4.4 mm in length (C) Sagittal section, (D) Coronal section.



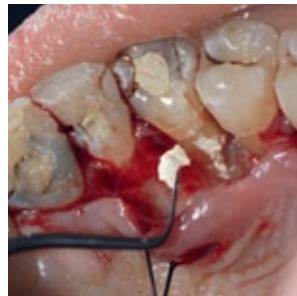**Fig. 4:** Flap lifting and cavity preparation.



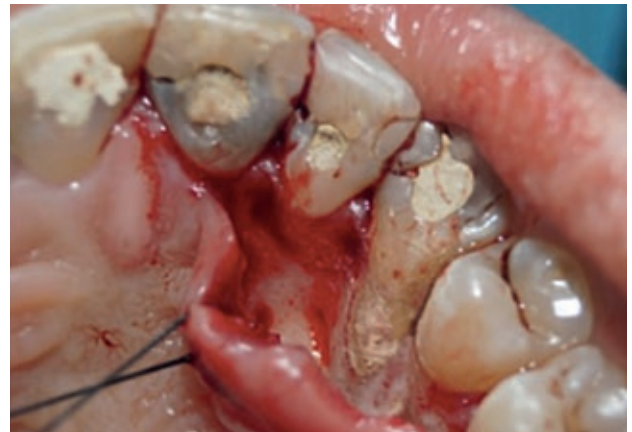**Fig. 5:** Preparation of Biodentine™.



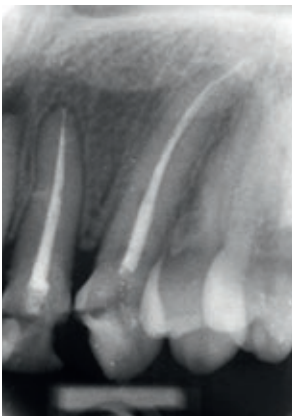
**Fig. 6:** Biodentine™.



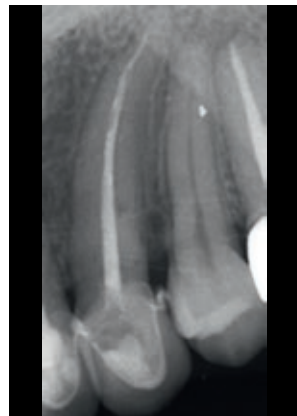**Fig. 7:** Placement of Biodentine™ in the affected area.



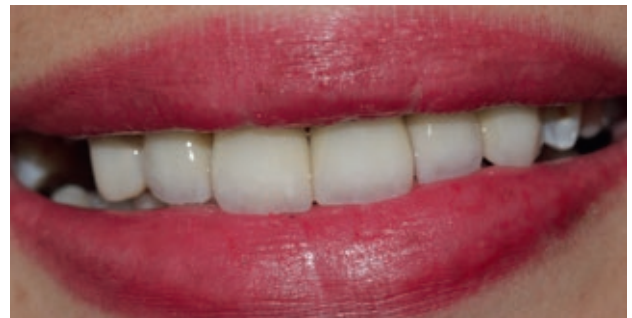**Fig. 8:** Root reconstruction.



**Fig. 9:** Final radiography.



**Fig. 10:** Follow-up radiography at 15 months.



**Fig. 11:** Final extraoral photograph.

Under local anesthesia with 2% Mepivacaine® (Septodont, France), the surgical procedure was begun; through an intrasulcular incision made in the palatal area from tooth 11 to tooth 25, a full-thickness mucoperiosteal flap was lifted using a Prichard periosteal elevator (Hu-Friedy USA), and curettage was performed using a Varios 370 ultrasound (NSK Corporation, Japan) and curettes (Hu-Friedy USA) (*Fig. 4*). Once the perforation was exposed, a single dose of Biodentine™ was prepared; mixing 5 drops of the liquid into the powder at a speed of 4000 oscillations/min for 30 seconds (*Fig. 5 and 6*) a uniform creamy mixture was obtained, which was

then applied to the cavity in layers, and after checking the root reconstruction (*Fig. 7 and 8*) the flap was repositioned and sutured; ten days after surgery, the stitches were removed with no symptoms or complications presented, and root canal therapy was performed; instrumentation was conducted using ProTaper Next (Dentsply Maillefer, Switzerland), irrigation performed with 5.25% sodium hypochlorite, and sealing carried out using a modified lateral technique with ultrasound (*Fig. 9*) and the patient referred to prosthesis for rehabilitation. 6 and 15 months after sealing, resorption was observed with successful treatment (*Fig. 10 and 11*).

# Discussion

Root resorption associated with periodontal disease is a slow process that normally occurs from the bone crest and extends to the apical area; it is an asymptomatic lesion, usually with an oval shape, and though the connective tissue is very similar to that of the alveolar bone, the cementum is not innervated, so the patient does not present painful symptoms; the teeth most susceptible to suffer root resorption are those with thin roots, such as the lateral, central and premolar teeth - this occurs less frequently in the canines, which gives the present case its relevance.<sup>4,5,13</sup>

Biodentine™ (Septodont, France) has been shown to be a material that induces the formation of pulp and mineralized tissues, since it promotes the secretion of growth factor beta 1, as well as inducing the expression of markers such as

osteopontin, alkaline phosphatase and RUNx2, in addition to hydroxy-apatite when it comes in direct contact with tissue fluids.<sup>10, 14,15</sup>

It has been shown to adhere both chemically and mechanically to dentin, and has low solubility; furthermore, Marconyak et al. have shown that compared to other materials such as ProRoot® MTA or MTA Angelus®, Biodentine™ also causes less discoloration, because it does not contain heavy metals, which moreover may also be harmful to health. Due to the great diversity of uses for Biodentine™, we can offer better treatment options, and have the certainty of positive results, as were obtained in the present case, for which we have X-rays and clinical images showing favorable evolution over 15 months.<sup>12,14,16</sup>

## Authors:

### Tenorio Fernando

Specialist in Oral Pathology, Master in Dental Sciences, Full-Time Professor, Level B, Head of the Oral and Maxillofacial Pathology Histopathological Diagnosis Laboratory, Interdisciplinary Research Laboratory, ENES/UNAM, León Unit, 37684 Guanajuato, Mexico.  
ftenorioenes@gmail.com

### Campos Paola

Specialist in Endodontics, Master's in Education, Course Professor, Level B, Dentistry Degree Studies, ENES/UNAM, León Unit, 37684 Guanajuato, Mexico.  
diente8@gmail.com

### Mancera Navarro Ana Karen

Master's student at the ENES/UNAM León Unit, 37684 Guanajuato, Mexico.  
annamannav@gmail.com



## References

---

1. Patel S, Kanagasingam S, Pitt T. External cervical resorption: a review. *JOE*, 2009 May;35(5):616-25.
2. Krishnan V. Critical issues concerning root resorption: A contemporary review. *World J Orthod*, 2005, 6(1): 30-40.
3. Kandalgaonkar SD, Gharat LA, Tupsakhare SD, Gabhane MH. Resorción Cervical Invasiva: Una Revisión. [Invasive Cervical Resorption: A review] *J Int Oral Health* 2013; 5 (6): 124-30.
4. Kanas RJ, Kanas SJ. Dental root resorption: a review of the literature and a proposed new classification.
5. Kim Y, Lee CY, Kim E, Roh BD. Invasive cervical resorption: treatment challenges. *Restor Dent Endod*. 2012;37(4):228-31.
6. Heithersay GS. Clinical, radiologic, and histopathologic features of invasive cervical resorption. *Quintessence Int*. 1999;30(1):27-37.
7. Tyrovola JB, Spyropoulos MN, Makou M, Perrea D. Root resorption and the OPG/RANKL/RANK system: a mini review. *J Oral Sci*. 50. Japan 2008. p. 367-76.
8. Gupta PK, Garg G, Kalita C, Saikia A Evaluation of Sealing Ability of Biodentine™ as Retrograde Filling Material by Using two different Manipulation Methods: An In Vitro Study. *J Int Oral Health* 2015 Jul;7(7):111-4.
9. Hshem D, Mannocci F, Patel S, Manohara A, Brown JE, Watson TF, Banerjee A. Clinical and radiographic assessment of the efficacy of calcium silicate indirect pulp capping: a randomized controlled clinical trial. *J Dent Res*. 2005 Apr; 94(4):562-8.
10. Silva L, Pieroni K, Nelson-Fiho P, Silva R, Hernandez-Gatón P, Lucisano MP, Paula-Silva F, de Queiroz A. Furcation Perforation: Periradicular Tissue Response to Biodentine™ as a Repair Material by Histopathologic and Indirect Immunofluorescence Analyses. *J Endod* 43(7):1137-1142.
11. N. Butt, S. Talwar, S. Chaudhry, et al. Comparison of physical and mechanical properties of mineral trioxide aggregate and Biodentine™. *Indian J Dent Res*, 25 (2014), pp. 692-697.
12. Cornélio A.L., Rodrigues E.M. Salles L.P, et al. Bioactivity of MTA Plus, Biodentine™ and experimental calcium silicate-based cements in human osteoblast-like cells. *Int Endod J*, 50 (2017), pp. 39-47.
13. Fuss Z, Tsesis I, Lin S. Root resorption-diagnosis classification and treatment choices based on stimulation factors. *Dent Traumatol* 2003; 19:175-182.
14. Laurent P, Camps J, About I, Biodentine™ induces TGF-β1 release from human pulp cells and early dental pulp mineralization. *Int Endod J*, 45 (2012), pp. 439-448.
15. Zhao W, Wang J., Zhai W, et al. The self-setting properties and in vitro bioactivity of tricalcium silicate. *Biomaterial*. 2005 (26), pp 773-739.
16. Parirokh M, Torabinajad M. Mineral trioxide aggregate: a comprehensive literature review-part III: clinical applications, drawbacks, and mechanism of action. *J Endod*, 2010 (36): 400-413.

# Sealing of a perforated furcation with Biodentine™

Dr. Alberto Díaz Tueme & Dr. Gisella Cañaveras Zambrano

## Introduction

In recent years the materials of choice for sealing accidental perforations of pulp chamber floor and/or walls during endodontic treatment have been based on tricalcium silicate. The reasons for using these materials are good dimensional stability, excellent marginal adap-

tation, bioactive capacity, resistance, and excellent performance in the presence of humidity. They need this humidity to harden, which means that they are suitable for use in different circumstances, particularly in cases of perforation.

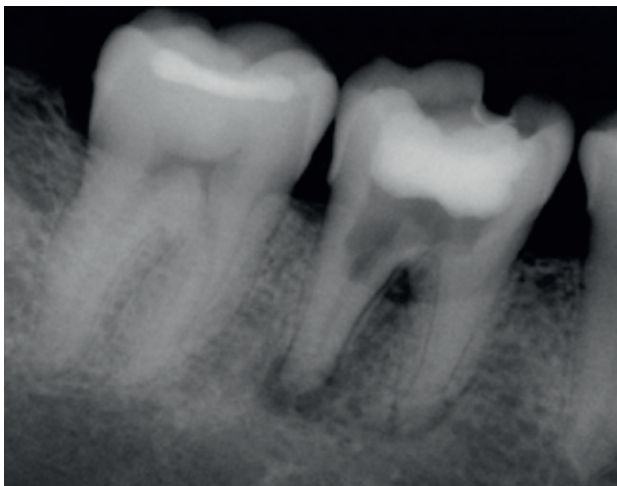


Fig. 1

## Case report

Thirty-six-year-old male patient, after attending his dentist on several occasions for root canal procedures in the first lower right molar. The patient presented with pain, particularly pressure pain. The x-ray image shows a radiolucent area in the area of the furcation and in the periapexes of both roots. Considerable destruction of the tooth structure was also observed, particularly in the furcation area. (Fig. 1). The patient stated that his dentist was unable to locate the root canals.

The x-ray image revealed a perforation, so it was decided to treat the case following prior consent and an uncertain prognosis. The patient accepted the conditions as he wished to maintain his tooth.

The temporary filler was removed and a cotton swab was found packed inside the pulp chamber. From the odour, it seemed to have been soaked in cresol liquid (Fig. 2). Copious irrigation with 2% sodium hypochlorite was done, and two canals in the mesial roots (MB and ML) and one distal canal were detected (Fig. 3). A perforation of around 2 mm x 2 mm was also located at the base of the furcation where it joined the lingual axial wall (Fig. 4). The instrumentation for the root canals was completed, medicating them with calcium hydroxide, and

the entry to the canals was filled with small cotton swabs. The perforation was sealed with Biodentine™ (Fig. 5) and an x-ray taken (Fig. 6). The patient was asked to return at 10 days to remove the calcium hydroxide, copiously rinsing with 2% sodium hypochlorite and washing the pulp chamber (Fig. 7). The canals were plugged and the pulp chamber filled with glass ionomer cement: the patient was sent to his dentist for definitive restoration, suggesting the placing of a crown without post (Fig. 8).

X-rays and clinical appearance at two years are shown. (Figs. 9 and 10), showing the disappearance of the radiolucent areas (Furcation and Periapex). The molar is functional and asymptomatic.

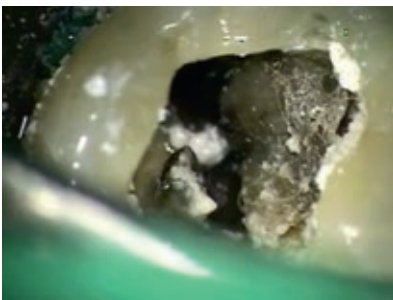


Fig. 2

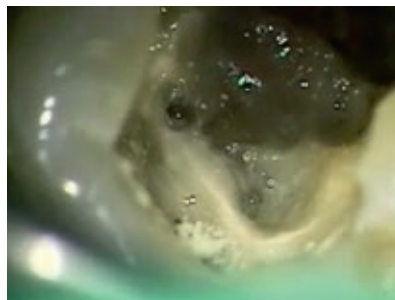


Fig. 3

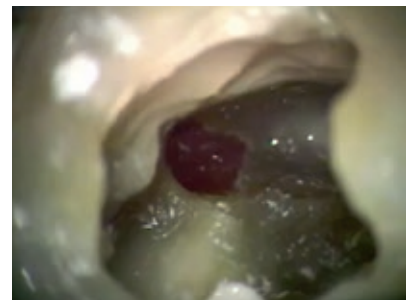

Fig. 4

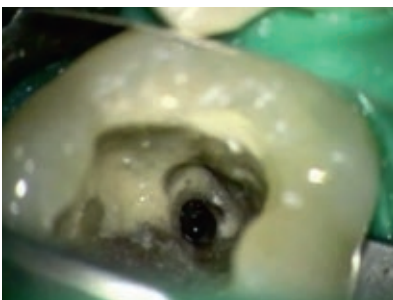


Fig. 5

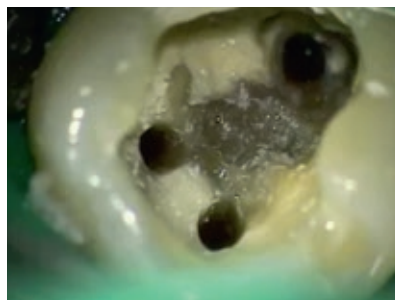

Fig. 6

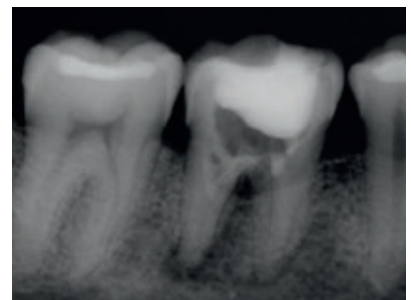


Fig. 7

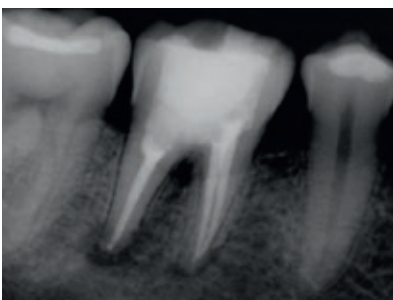


Fig. 8

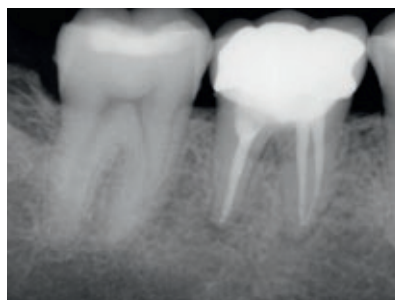


Fig. 9

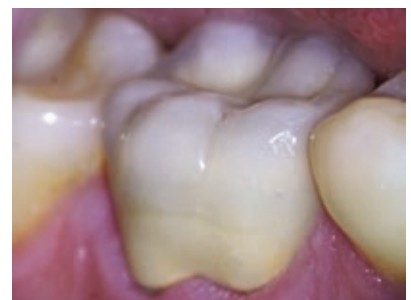

Fig. 10

# Conclusion

Biodentine™ is a material that fulfils the requirements for material of choice in cases of accidental perforation of pulp chamber walls and/or floor during endodontic treatment, thanks to

its performance in humid media, its bioactive adhesion to dentine, its biocompatibility and its thrust and tractive force.

## Authors:



### Dr. Alberto Díaz Tueme

Graduate of Universidad Autónoma Metropolitana.

Doctor in Endodontics, Ciero (Mexico D.F.).

Former professor at Universidad Autónoma Metropolitana and Universidad de Guadalajara.

Postgraduate Professor in Endodontics at Universidad Autónoma de Guadalajara.

Member of a number of professional associations in the speciality.

Vice-chairman of the Mexican Association of Endodontics - Endodontics Specialists Section.



### Dr. Gisella Stella Cañaveras Zambrano - Endodontist

Dental Surgeon, studied at the Universidad Autónoma Metropolitana in the City of Barranquilla, Colombia 1993 – 1998.

Ph. D in Endodontics from the Universidad Autónoma de Guadalajara, Mexico 1998 - 2000.

President of the Jalisco Endodontics Association 2010 - 2011.

Member no. 400 of the Mexican Council of Endodontists - 2006 to date.

Member of the Mexican Endodontics Association – Specialists in Endodontics Section.

Member of the Mexican Dental Association.

Member of the Jalisco Odontology Association.

Treasurer, Jalisco Endodontics Association - 2014 to date.

Coordinator of commercial exhibition and member of the Organizing Committee of the Congress of the Mexican Endodontics Association - Endodontics Specialists Section.

Ph. D. Professor in Endodontics at the Universidad Autónoma de Guadalajara - 2014 to date.

Attendance at more than 60 courses on Endodontics-related subjects.

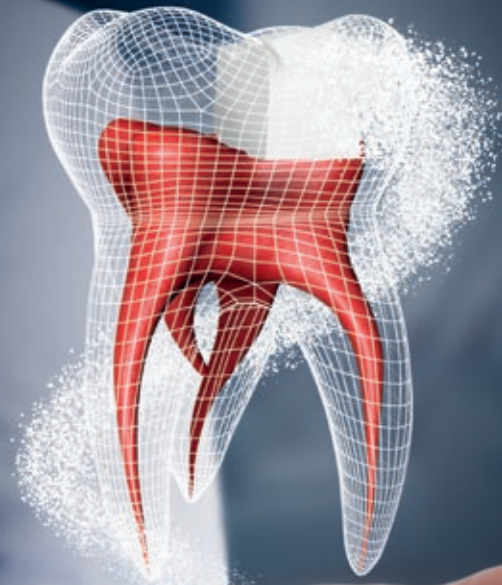
Only practices in Endodontics.

## References

1. Wang, Z. Bioceramic materials in endodontics. *Endodontic topics*, 2105, 32, 3-30.
2. About, I. Biodentine™: from biochemical and bioactive properties to clinical applications. *Giornale italiano di endodonzia*. 2016, 30, 81-88.
3. Haapasalo, M et Al. Clinical use of bioceramic materials. *Endodontic topics*, 2015, 32, 97-117.

# Biodentine™

“First ever  
Biological  
Bulk Fill”



Pediatrics

Restorative

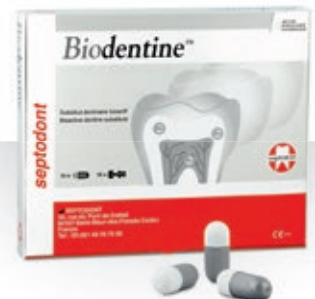Endodontics

For vital pulp therapy, bulk-filling the cavity with Biodentine™ makes your procedure better, easier and faster:

- Pulp healing promotion: proven biocompatibility and bioactivity
- Reduced risk of failure: strong sealing properties
- Only one material to fill the cavity from the pulp to the top
- Similar mechanical behavior as natural dentin: ideal for bulk filling

The final enamel restoration will be placed within 6 months.

Innovative by nature



ACTIVE  
BIOSILICATE  
TECHNOLOGY

Please visit our website for more information  
[www.septodont.com](http://www.septodont.com)





The Dental Pharmaceutical Company

---

INNOVATIVE, SAFE AND EFFECTIVE SOLUTIONS FOR DENTISTRY WORLDWIDE